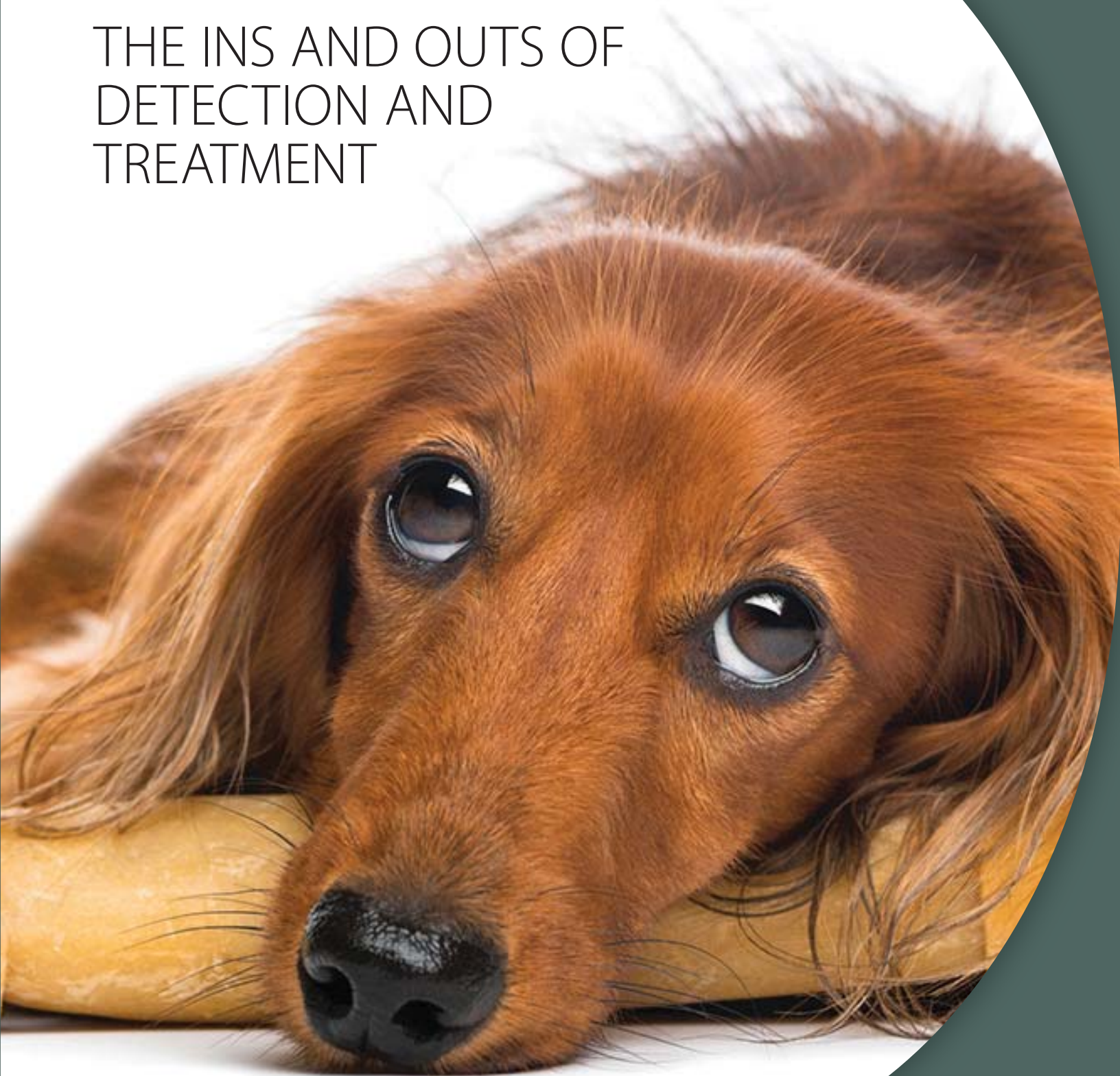


Canine Cushing's Case Files:

THE INS AND OUTS OF
DETECTION AND
TREATMENT



Canine Cushing's Case Files:

THE INS AND OUTS OF DETECTION AND TREATMENT

CLINICAL ARTICLES

- 6 **Case file: DALI**
by Audrey K. Cook, BVM&S, MRCVS, DACVIM
- 8 **Case file: PRINCESS**
by Lori Thompson, DVM, DACVD
- 10 **Case file: MITCH**
by David Bruyette, DVM, DACVIM
- 12 **Case file: HOLLY**
by Christopher G. Byers, DVM, DACVECC, DACVIM
- 14 **Case file: LIBBY**
by Todd M. Archer, DVM, MS, DACVIM
- 16 **Case file: BOCA**
by Cynthia Nichols, DVM
- 18 **Case file: HOWIE**
by Christopher G. Byers, DVM, DACVECC, DACVIM
- 20 **Case file: CALLIE**
by Orla Mahony, MVB, DACVIM, DECVIM
- 22 **Dogs with recurring pyoderma**
by Thomas Lewis, DVM, DACVD
- 24 **5 questions veterinarians ask the
Dechra Veterinary Products Technical
Services Team**

PRACTICE-RELATED ARTICLES

- 26 **Your veterinary team's role in identifying
dogs with hyperadrenocorticism**
- 28 **Your veterinary team's role in
treating and monitoring dogs with
hyperadrenocorticism**
- 30 **The economics of managing
hyperadrenocorticism in dogs**
by Fritz Wood, CPA, CFP
- 32 **Avoiding practitioner pitfalls
with canine Cushing's cases**
by Andy Roark, DVM, MS

DECHRA VETERINARY PRODUCTS SUPPLEMENTAL RESOURCES

- 34 **Diagnosis, Treatment and Monitoring
of Hyperadrenocorticism**
- 37 **Technical Brochure for VETORYL®
Capsules (trilostane)**

When you know *the ins and outs* of something, it means you know the intricate details, fine points, peculiarities, or technicalities of a certain subject. The phrase *the ins and outs* also has a second meaning — the windings of a road or path. When faced with a case of hyperadrenocorticism in a dog, you may feel you are on a winding path. Often the diagnosis is not straightforward or obvious. The clinical signs can be subtle or have a gradual onset. And because hyperadrenocorticism commonly affects older dogs, clients may attribute the changes they're observing to "normal aging."

Dechra Veterinary Products, the manufacturer of VETORYL® Capsules (trilostane), understands how challenging the diagnosis and management of canine hyperadrenocorticism, or Cushing's syndrome, can be. The disease can manifest in many different ways and, of course, each patient is unique. To help practitioners and staff recognize the disease and provide the best treatment for these patients, Dechra Veterinary Products sponsored a 12-article series for your reference, *Canine Cushing's Case Files: The Ins and Outs of Detection and Treatment*, that was inserted in *dvm360* magazine throughout 2013. That series is the core of this e-book, along with two bonus case reports, available only here.

The veterinarians who managed the eight clinical cases in

this e-book describe their diagnostic process and their treatment protocol and share their personal perspective on each case. In addition, a veterinary dermatologist provides insight on why practitioners should consider hyperadrenocorticism in dogs that have recurring pyoderma.

As with any type of case, client communication, involvement of the entire veterinary practice team, and understanding the financial impact on practice health are critical to skillfully managing patients with chronic diseases such as Cushing's syndrome. To address such issues, this e-book also includes articles on:

- Answers to the top five questions that veterinarians ask the Dechra Veterinary Products Technical Services Team about canine hyperadrenocorticism and VETORYL® Capsules (trilostane).
- The veterinary practice team's role in educating and communicating with clients about identifying, treating, and monitoring dogs with hyperadrenocorticism
- The economics and financial impact of managing Cushing's patients on your practice's bottom line
- Ways to avoid common practitioner pitfalls when providing long-term healthcare for a patient with a chronic disease

At the back of this e-book, we have included additional algorithms and other supporting documents we hope you will find helpful — *Diagnosis, Treatment, and Monitoring of Hyperadrenocorticism* (p. 34-36), and the full *Technical Brochure for VETORYL® Capsules (trilostane)* (p. 37-52).

Beyond this e-book, we provide a number of Cushing's-related online resources at www.dechra-us.com and Continuing Education modules in our Dechra Academy (click on the Dechra CE tab on the Dechra website). The Dechra Academy contains multiple complimentary RACE-approved CE modules on endocrine diseases presented by key opinion leaders. Diagnostic and treatment algorithms, client brochures, patient monitoring forms, case studies and more can be found on the Dechra US website. To order printed copies of any of the resources contact Dechra Customer Support at (866) 683-0660. For case consultations please contact our highly skilled Veterinary Technical Support Team at (866) 933-2472.

The main purpose of this e-book and all of our other resources is to let you know that we are here to help you be successful when you are faced with canine Cushing's patients. We want to help guide you along the sometimes winding path of diagnosing and managing dogs with hyperadrenocorticism and provide you with the information and tools you need to master the details, the fine points — the ins and outs — of canine Cushing's syndrome.

—Dechra Veterinary Products

Hyperadrenocorticism affects many adult dogs. Whether the disease is pituitary-dependent (80% to 85% of spontaneous cases) or adrenal-dependent (15% to 20% of cases), the clinical and laboratory abnormalities associated with it result from chronic hypercortisolemia. Clinical signs of hyperadrenocorticism at the time of diagnosis can vary widely, and they develop so gradually that owners often mistake the signs for "normal" aging. Being aware of the more subtle signs of canine hyperadrenocorticism can be key to early diagnosis and initiation of therapy.

Whenever possible, pituitary-dependent hyperadrenocorticism and adrenal tumors should be differentiated to help guide therapy and patient monitoring. Early diagnosis and management of canine hyperadrenocorticism may not only improve the patient's clinical signs but may also keep the more severe consequences of Cushing's syndrome from developing.

Common clinical signs of canine hyperadrenocorticism

- Polyuria (owners may complain of housesoiling)
- Polydipsia
- Polyphagia (owners may complain of food stealing or excessive begging)
- Alopecia
- Recurrent skin disease
- Lethargy
- Pendulous abdomen
- Excessive panting
- Thin skin

Other clinical signs may include hypertension, comedones, seborrhea, heat intolerance, hyperpigmentation, calcinosis cutis, bruising, facial paralysis, failure to cycle, clitoral hypertrophy, testicular atrophy, poor hair regrowth after surgery, recurrent urinary tract infections, demodicosis in a middle-aged or older dog, and a first incidence of pyoderma in an older dog.

VETORYL® Capsules (trilostane) are the only FDA-approved drug indicated for the treatment of pituitary-dependent and adrenal-dependent hyperadrenocorticism (PDH and ADH) in dogs. Trilostane, the active ingredient, blocks hormone production in the adrenal cortex by competitive enzyme inhibition and is clinically effective in treating dogs with PDH and ADH; however, it does not affect tumor growth.

- The use of VETORYL Capsules is contraindicated in dogs that have demonstrated hypersensitivity to trilostane.
- Do not use VETORYL Capsules in animals with primary hepatic disease or renal insufficiency.
- Do not use in pregnant dogs. Studies conducted with trilostane in laboratory animals have shown teratogenic effects and early pregnancy loss.
- The most common adverse reactions reported are poor/reduced appetite, vomiting, lethargy/dullness, and weakness.
- Occasionally, more serious reactions, including severe depression, hemorrhagic diarrhea, collapse, hypoadrenocortical crisis or adrenal necrosis/rupture may occur, and may result in death.

Treat their Hyperadrenocorticism. Help restore their vitality.




Dechra
Veterinary Products

VETORYL® Capsules (trilostane) are the only FDA veterinary-approved treatment for pituitary-dependent and adrenal-dependent hyperadrenocorticism in dogs (Cushing's syndrome). They contain the active ingredient trilostane, which blocks the excessive production of cortisol.

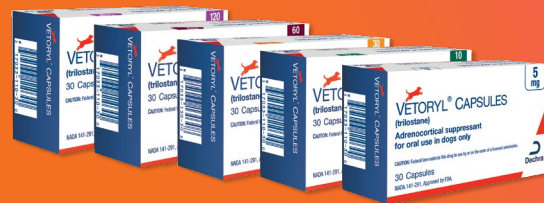Daily administration of **VETORYL Capsules** can greatly reduce the clinical signs associated with Cushing's syndrome, helping to restore the dog's vitality. Clinical studies demonstrated that treatment with **VETORYL Capsules** resulted in decreased thirst, decreased frequency of urination, decreased panting, and improvement of appetite and activity.¹ Activity levels began to show improvement within 14 days of treatment.

As with all drugs, side effects may occur. In field studies and post-approval experience, the most common side effects reported were: anorexia, lethargy/depression, vomiting, diarrhea, elevated liver enzymes, elevated potassium with or without decreased sodium, elevated BUN, decreased Na/K ratio, hypoadrenocorticism, weakness, elevated creatinine, shaking, and renal insufficiency. In some cases, death has been reported as an outcome of these adverse events. VETORYL Capsules are not for use in dogs with primary hepatic or renal disease, or in pregnant dogs. Refer to the prescribing information for complete details or visit www.dechra-us.com.

24 Hour Technical Support: 866-933-2472 | www.dechra-us.com | support@dechra.com

VETORYL is a trademark of Dechra LTD. ©2015, Dechra Ltd.
NADA 141-291, Approved by FDA
CAUTION: Federal law restricts this drug to use by or on the order of a licensed veterinarian.
¹<https://animaldrugsatfda.fda.gov/adafda/app/search/public/document/downloadFoi/855>


VETORYL® CAPSULES
(trilostane)



Dechra Veterinary Products US and the Dechra D logo are registered trademarks of Dechra Pharmaceuticals PLC.

Canine Cushing's Case Files:

THE INS AND OUTS OF DETECTION AND TREATMENT

CONTRIBUTING AUTHORS



Todd M. Archer,
DVM, MS, DACVIM



David Bruyette,
DVM, DACVIM



Christopher G. Byers,
DVM, DACVECC, DACVIM



Audrey K. Cook,
BVM&S, MRCVS, DACVIM,
DECVIM, DABVP



Thomas Lewis,
DVM, DACVD



Orla Mahony,
MVB, DACVIM, DECVIM



Cynthia Nichols, DVM



Andy Roark, DVM, MS



Lori Thompson,
DVM, DACVD



Fritz Wood, CPA, CFP

© 2018 Dechra Veterinary Products

www.dechra-us.com • www.dechra-us.com/CE

Dechra Veterinary Products

7015 College Blvd., Suite 525
Overland Park, KS 66211

Veterinary Technical Support: (866) 933-2472

Customer Support: (866) 683-0660

Case file: DALI

10-year-old, spayed female dachshund weighing 9 lb (4.1 kg)

Presenting complaint and history

Dali was referred to Texas A&M's Veterinary Teaching Hospital for evaluation of a mammary mass that had progressively enlarged over a three-month period. Several years before referral, Dali had two malignant mammary masses removed. Dali was receiving levothyroxine, and recent post-pill thyroxine concentrations showed effective control of her hypothyroidism.

Referral evaluation

Dali had a 2- x 3-cm nodular mass (and three smaller nodules) associated with her third right mammary gland. Dali displayed a plantigrade stance of the forelimbs, and her abdomen was pendulous, with thin skin (*Figure 1*).

Laboratory test results

A serum chemistry profile revealed increased alkaline phosphatase, alanine aminotransferase, and gamma glutamyl transferase activities. Dali's serum cholesterol concentration was also increased. A complete blood count showed a stress leukogram with thrombocytosis. Her urine specific gravity was 1.008, and a urine bacterial culture was negative. Although the owner had not reported that Dali exhibited abnormal thirst or excessive urination, the low urine specific gravity indicated polyuria and polydipsia.

Cytologic examination and imaging

The results of a fine-needle aspirate and cytologic examination of the mammary mass indicated carcinoma. Thoracic radiographs were unremarkable; however, abdominal ultrasonography revealed diffuse hyperechoic hepatomegaly, and both adrenal glands were substantially enlarged (*Figure 2*).



Audrey K. Cook, BVMS, MRCVS, DACVIM, DECVIM, DABVP
For 10 years, Dr. Cook owned a specialty referral practice in Virginia. In 2007, she joined the faculty of Texas A&M University, where she is an associate professor in Small Animal Internal Medicine.



FIGURE 1. Dali exhibited thin ventral abdominal skin with poor elasticity.

Differential diagnoses

Dali's tentative diagnoses were mammary carcinoma and hyperadrenocorticism. Although the ultrasonographic findings strongly suggested hyperadrenocorticism, adrenomegaly does not provide a definitive diagnosis. A low-dose dexamethasone suppression (LDDS) test was done to evaluate the pituitary-adrenal axis.

LDDS test results

Dali's LDDS test results indicated hyperadrenocorticism. Although the four-hour post-dexamethasone cortisol concentration (2.95 µg/dl) was lower than the baseline (4.73 µg/dl) and 8-hour post-dexamethasone (5.08 µg/dl) cortisol concentrations, it was greater than 1.4 µg/dl (reference range) and did not suppress to more than 50% of the baseline concentration. Therefore, the LDDS test results did not confirm pituitary-dependent hyperadrenocorticism. However, the ultrasonographic findings excluded an adrenal tumor.

Treatment

Prompt removal of Dali's mammary carcinoma was recommended because of its size and metastatic potential. Compromised healing due to hyperadrenocorticism and increased risk of acute perioperative complications such as pulmonary thromboembolism and infection were of concern, but the decision was made to treat the hyperadrenocorticism postoperatively. Dali's

potential to develop thromboembolic problems was adequately managed medically, and a mastectomy was performed.

The day after surgery, Dali was comfortable and eating well. Treatment for hyperadrenocorticism with VETORYL® Capsules (trilostane) was started, at a dose of 2.4 mg/kg, given orally once daily with food. Dali was discharged later that day and was to continue to receive levothyroxine; antibiotic treatment to prevent postoperative infection was also prescribed.

Dali's owners were told to monitor Dali closely and if problems were observed, to discontinue VETORYL Capsules and have Dali re-evaluated immediately.

Follow-up evaluations and Dali's response

At Dali's recheck visit two weeks later, the incision site appeared to be healing well and the

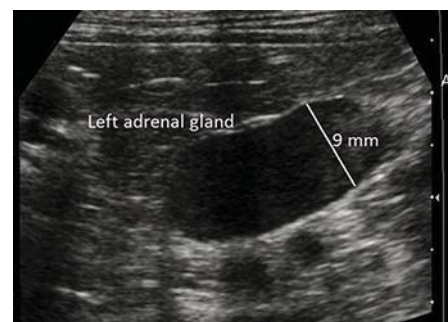

FIGURE 2. An ultrasonographic image of Dali's left adrenal gland reveals adrenomegaly (*Image courtesy of Texas A&M Radiology Service*).

antibiotic therapy was complete. The owner reported that Dali was eating well and urinating less frequently. The results of a serum chemistry profile were similar to the results of a previous one, and Dali's serum electrolyte concentrations were normal. An adrenocorticotrophic hormone (ACTH) stimulation test was performed four hours after VETORYL® Capsules (trilostane) administration to assess Dali's adrenal function. The baseline cortisol concentration was 5.3 µg/dl, and the post-ACTH cortisol concentration was 13.8 µg/dl (target post-ACTH cortisol concentration <9.1 µg/dl). Dali's VETORYL Capsules dose was increased to 5 mg/kg once daily.

Four weeks postoperatively

Dali was presented for a recheck examination and suture removal (postponed to allow more time for healing) two weeks later. Dali was doing well at home and was drinking less than before VETORYL Capsules treatment. The skin on her ventrum was still thin, but hair growth was apparent around the surgical site. Her serum electrolyte concentrations were normal. An ACTH stimulation test showed a baseline cortisol concentration of 4.5 µg/dl and a post-ACTH cortisol concentration of 7.7 µg/dl. VETORYL Capsules were continued at the same dose. The owner was advised to present Dali for a recheck examination in four weeks.

Ten weeks postoperatively

Dali was presented six weeks later and the owner reported that Dali was active and energetic. The hair around Dali's surgical site had regrown, and the thickness and elasticity of her ventral abdominal skin had improved. The owner declined laboratory tests other than an ACTH stimulation test. The results were optimal, with a baseline cortisol concentration of 3.3 µg/dl and a post-ACTH cortisol concentration of 4.4 µg/dl. VETORYL Capsules were continued at 5 mg/kg once daily.

Dali's long-term response

Eighteen months postoperatively, Dali exhibits no evidence of recurrence or metastasis of the mammary carcinoma and her hypothyroidism continues to be managed medically. Her hyperadrenocorticism is effectively controlled with VETORYL Capsules (Figure 3), adjusted from 2.4 mg/kg to 5 mg/kg once daily, depending

VETORYL® Capsules (trilostane) are the only FDA-approved drug indicated for the treatment of pituitary-dependent and adrenal-dependent hyperadrenocorticism (PDH and ADH) in dogs. Trilostane, the active ingredient, blocks hormone production in the adrenal cortex by competitive enzyme inhibition and is clinically effective in treating dogs with PDH and ADH; however, it does not affect tumor growth.

- The use of VETORYL Capsules is contraindicated in dogs that have demonstrated hypersensitivity to trilostane.
- Do not use VETORYL Capsules in animals with primary hepatic disease or renal insufficiency.
- Do not use in pregnant dogs. Studies conducted with trilostane in laboratory animals have shown teratogenic effects and early pregnancy loss.
- The most common adverse reactions reported are poor/reduced appetite, vomiting, lethargy/dullness, and weakness.
- Occasionally, more serious reactions, including severe depression, hemorrhagic diarrhea, collapse, hypoadrenocortical crisis or adrenal necrosis/rupture may occur, and may result in death.

on her clinical signs and routine laboratory and adrenal function test results.

Dr. Cook's perspective

Dali's case highlights the need to carefully weigh the risks of surgery in a dog with untreated hyperadrenocorticism, such as poor healing, infection, and thromboembolic problems. Also keep in mind that bilateral adrenomegaly is not diagnostic for hyperadrenocorticism and the diagnosis must be confirmed by adrenal function testing.

Concurrent diseases may affect the results of some of these tests. The LDDS test is more sensitive than the ACTH stimulation test, but it is less specific and more likely to be affected by concurrent disease, including neoplasia. Adre-

nal function test results must always be evaluated carefully in dogs with concurrent diseases, and a high index of suspicion for hyperadrenocorticism should be present before performing either test. Because Dali's small mammary tumors were unlikely to cause systemic illness, we were comfortable diagnosing hyperadrenocorticism based on her clinical examination and routine laboratory and LDDS test results.

As in Dali's case, when treating hyperadrenocorticism with VETORYL Capsules, decisions to adjust the dose should take into account the clinical status of the patient, the cortisol concentrations, and the owner's satisfaction.

This case was solicited from the prescribing veterinarian and may represent an atypical case study. Similar results may not be obtained in every case.




FIGURE 3. Dali, 18 months after a mastectomy and treatment for hyperadrenocorticism with VETORYL® Capsules (trilostane). Dali's hair coat and abdominal silhouette are not suggestive of hyperadrenocorticism. She still has a slightly plantigrade stance in the forelimbs.

Case file: PRINCESS

13-year-old spayed female Maltese weighing 9.2 lb (4.2 kg)

Patient history

Princess has a five-year history of pedal pruritus that routinely appears in the summer and fall and responds to topical and oral antibiotic and corticosteroid treatment. About 18 months ago, Princess also developed facial pruritus, but her facial and pedal pruritus did not respond to this therapy, so she was referred for further dermatologic evaluation.

Referral evaluation

Princess' owners reported no behavior changes other than those associated with facial and pedal pruritus.

Physical examination findings

Physical examination revealed that Princess' popliteal lymph nodes were mildly enlarged. Her hair coat was diffusely thin, and she had a pot-bellied appearance. Her ventral abdominal skin was moderately striated with reduced elasticity. Numerous erythemic papules, pustules, and epidermal collarettes (variably crusted) were present over her entire body. The periocular regions and muzzle were the most severely affected (*Figure 1*). The dorsal, ventral, and interdigital aspects of all four paws were moderately alopecic and erythemic.

Diagnostic test results

Cytologic examination of skin scrapings were positive for all life stages of *Demodex canis*. Cytologic examination of impression smears and acetate tape preparation samples from the muzzle and abdomen revealed 1+ to 2+

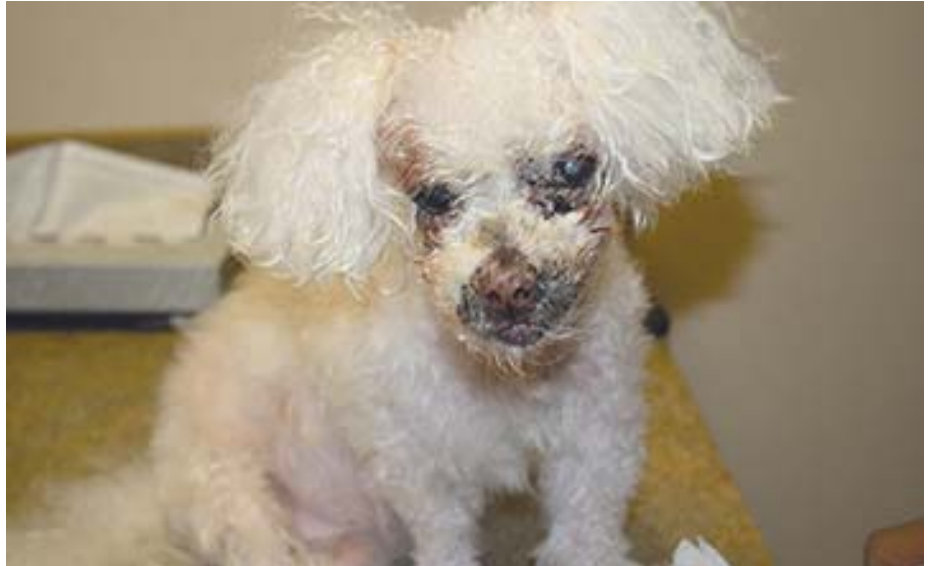

FIGURE 1. Princess before treatment for demodicosis, pyoderma, and hyperadrenocorticism. She exhibits perioral and periocular crusting, hyperpigmentation, erythema, and a pot-bellied appearance.

cocci along with numerous degenerate neutrophils. Samples for fungal culture (dermatophyte test medium) were obtained to rule out dermatophytosis.

A complete blood count showed no abnormalities; a serum chemistry profile revealed elevated alkaline phosphatase (1,456 IU/L; reference range = 12 to 118 IU/L) and gamma-glutamyltransferase activities (62 IU/L; reference range = 1 to 12 IU/L). Princess' total T_4 concentration was low at 0.8 $\mu\text{g}/\text{dl}$ (reference range = 1.0 to 4.0 $\mu\text{g}/\text{dl}$), but her free T_4 and TSH concentrations were within normal limits, indicating sick euthyroid syndrome.

Medical management of Princess' superficial pyoderma and demodicosis was initiated. However, at each of Princess' rechecks at three, six, and nine weeks, skin scraping results revealed that the *Demodex* species mite counts had not markedly decreased, despite appropriate treatment. The results of the previously submitted fungal culture were negative.

To determine whether hyperadrenocorticism was the underlying cause of Princess' adult-onset demodicosis, an adrenocorticotropic hormone (ACTH) stimulation test was

then performed. Princess' baseline cortisol concentration was 2.7 $\mu\text{g}/\text{dl}$ (reference range = 1.0 to 5.0 $\mu\text{g}/\text{dl}$) and her post-ACTH cortisol concentration was 47.3 $\mu\text{g}/\text{dl}$ (reference range = 8.0 to 17.0 $\mu\text{g}/\text{dl}$). An abdominal ultrasonogram revealed bilaterally enlarged adrenal glands with no evidence of an adrenal tumor.

Treatment and follow-up

Treatment for pituitary-dependent hyperadrenocorticism (PDH) with VETORYL® Capsules (trilostane) was started at a dose of 2.4 mg/kg given orally once daily with food. The pyoderma treatment had been completed, and medical management of the demodicosis was continued.

Initial follow-up visits

After 14 days, Princess' baseline cortisol concentration was 2.7 $\mu\text{g}/\text{dl}$, and her post-ACTH cortisol concentration was 10.3 $\mu\text{g}/\text{dl}$, which was above the value ($> 9.1 \mu\text{g}/\text{dl}$) suggested for increasing the VETORYL Capsules dose. However, Princess was doing well clinically, so it was decided to continue to monitor her at the same dose. Princess also continued to receive treatment for demodicosis.



Lori Thompson, DVM, DACVD

After receiving her DVM degree, Dr. Thompson completed a residency in veterinary dermatology. She opened Animal Dermatology Clinic in Indianapolis in October of 2009, where she served as the managing partner. In October of 2016, Dr. Thompson opened her own practice, Animal Allergy & Dermatology Center of Indiana.

VETORYL® Capsules (trilostane) are the only FDA-approved drug indicated for the treatment of pituitary-dependent and adrenal-dependent hyperadrenocorticism (PDH and ADH) in dogs. Trilostane, the active ingredient, blocks hormone production in the adrenal cortex by competitive enzyme inhibition and is clinically effective in treating dogs with PDH and ADH; however, it does not affect tumor growth.

- The use of VETORYL Capsules is contraindicated in dogs that have demonstrated hypersensitivity to trilostane.
- Do not use VETORYL Capsules in animals with primary hepatic disease or renal insufficiency.
- Do not use in pregnant dogs. Studies conducted with trilostane in laboratory animals have shown teratogenic effects and early pregnancy loss.
- The most common adverse reactions reported are poor/reduced appetite, vomiting, lethargy/dullness, and weakness.
- Occasionally, more serious reactions, including severe depression, hemorrhagic diarrhea, collapse, hypoadrenocortical crisis or adrenal necrosis/rupture may occur, and may result in death.

In 45 days, the *Demodex canis* counts had decreased significantly to a few dead mites. At 90 days, Princess' skin scraping results were negative, and treatment for demodicosis was discontinued. Her lymphadenopathy had resolved, new hair growth was present, and the owners reported Princess exhibited minimal pruritus.

Princess continued to receive 10 mg of VETORYL® Capsules (trilostane) daily, and ACTH stimulation tests were performed as recommended and the results were within normal limits. The owners declined a follow-up thyroid hormone panel as well as serum chemistry profiles as a component of monitoring.

Princess' long-term response

Five months after her initial referral presentation, Princess was presented again for evaluation of facial crusting and pruritus. Her owners had been out of town, and Princess had stayed with relatives who had discontinued her VETORYL Capsules for 30 days before this examination.

Results of skin scrapings and cytologic examination once again revealed demodicosis and a superficial bacterial infection. Treatment for pyoderma and demodicosis was reinitiated, and treatment for PDH with VETORYL Capsules 10 mg was again instituted.

Two weeks later, Princess's baseline cortisol concentration was 1.7 µg/dl and her post-ACTH cortisol concentration was 7.0 µg/dl. Follow-up skin scrapings and an ACTH stimulation

test were scheduled for one month later, but Princess was lost to follow-up after this visit.

Dr. Thompson's perspective

As is frequently the case, client compliance is a key to effectively managing patients with hyperadrenocorticism. Owners or caretakers may easily become complacent about administering medications for chronic diseases, and demodicosis and hyperadrenocorticism are no exceptions. Once the pet looks and starts acting normal again, owner compliance may suffer despite the veterinarian's best efforts to educate their clients.

It is also easy to see the rapid effects of discontinuing VETORYL Capsules. Maximal plasma levels of trilostane occur within 1.5 hours, returning to baseline levels within 12 hours, although large inter-dog variation occurs. In Princess' case, demodicosis recurred rapidly after she stopped receiving VETORYL Capsules to treat her PDH.

Providing client literature that explains hyperadrenocorticism and the necessity for long-term medical management (see www.dechra-us.com for client brochures), holding conferences in which all family members are educated about how the disease must be managed, and ensuring follow-up by the veterinarian and veterinary team (via phone calls or emails), will likely enhance your opportunities for successful treatment.



Client compliance is a key to effectively managing patients with hyperadrenocorticism. Owners or caretakers may easily become complacent about administering medications for chronic diseases, and demodicosis and hyperadrenocorticism are no exceptions.

This case was solicited from the prescribing veterinarian and may represent an atypical case study. Similar results may not be obtained in every case.



Case file: MITCH

12-year-old neutered male dachshund weighing 22 lb (10 kg)

Patient history and initial diagnostic workup

Mitch was presented to his primary care veterinarian for evaluation of polyuria and polydipsia of six months' duration. The dog's urine specific gravity was 1.010 and a serum chemistry profile revealed an alkaline phosphatase activity of 1,240 IU/L (reference range = 37 to 105 IU/L). The results of a complete blood count were within normal limits, and urine bacterial culture results were negative.

Adrenal function test results

The results of an adrenocorticotropic hormone (ACTH) stimulation test revealed a baseline cortisol concentration of 3.6 $\mu\text{g}/\text{dl}$ (reference range = 1.4 to 5 $\mu\text{g}/\text{dl}$) and a one-hour post-ACTH cortisol concentration of 12.9 $\mu\text{g}/\text{dl}$ (reference range = 5.5 to 20 $\mu\text{g}/\text{dl}$). Low-dose dexamethasone suppression (LDDS) test results revealed a resting cortisol concentration of 9.1 $\mu\text{g}/\text{dl}$ (reference range = 1.4 to 5 $\mu\text{g}/\text{dl}$) with

four- and eight-hour post-dexamethasone cortisol concentrations of 5.6 $\mu\text{g}/\text{dl}$ and 2.3 $\mu\text{g}/\text{dl}$ (reference range < 1.4 $\mu\text{g}/\text{dl}$), respectively.

The abnormal LDDS eight-hour cortisol concentration, in combination with more than 50% suppression in cortisol concentration during the test, was diagnostic of pituitary-dependent hyperadrenocorticism (PDH). Mitch was referred to VCA West Los Angeles Animal Hospital to be evaluated for treatment.

Referral evaluation

Physical examination revealed mild hepatomegaly and mild bilaterally symmetrical alopecia involving the ventral abdomen and thighs. Surgical, radiation, and medical treatment options for PDH were discussed with the owners, who opted for medical management.

Treatment and follow-up

Treatment with VETORYL® Capsules (trilostane) was begun at a dose of 3 mg/kg, given orally once daily in the morning with food. The owner was instructed to monitor Mitch's water consumption, urination, appetite, and activity level and to observe the dog for vomiting or diarrhea. A recheck physical examination and an ACTH stimulation test with serum electrolyte measurements were scheduled for 10 days after the start of the treatment.

Initial follow-up visits

At the 10-day recheck visit, the owners reported a marked reduction in Mitch's polyuria and polydipsia. The dog's serum sodium and potassium concentrations were within normal limits. An ACTH stimulation test performed four hours after administration of the VETORYL Capsules dose revealed pre- and post-ACTH cortisol concentrations of 1.6 and 5.1 $\mu\text{g}/\text{dl}$, respectively, indicating adequate inhibition of glucocorticoid production.

Based on these results and the improvement in clinical signs, the initial VETORYL Capsules dosage was continued. Mitch was scheduled for a 30-day post-treatment recheck examination.

During the subsequent visit, the owners reported that Mitch was more active and exhibited normal water consumption and urination. A morning urine sample collected by the owner showed a specific gravity of 1.036. The dog's serum sodium and potassium concentrations were normal, and an ACTH stimulation test revealed pre- and post-ACTH cortisol concentrations of 2.8 and 5.1 $\mu\text{g}/\text{dl}$, respectively, indicating adequate inhibition of glucocorticoid production.

The initial VETORYL Capsules dosage was continued, and a 90-day post-treatment recheck examination was scheduled.



**David Bruyette,
DVM, DACVIM**

Prior to his current position as CMO at Anivive Lifesciences, Dr. Bruyette was medical director at VCA West Los Angeles Animal Hospital and CEO of Veterinary Diagnostic Investigation and Consultation.

Mitch's long-term response

At his three- and six-month recheck visits, Mitch continued to be clinically normal, and his electrolyte concentrations remained within normal limits. The ACTH stimulation tests revealed post-ACTH cortisol concentrations of 5.2 µg/dl at three months and 5.9 µg/dl at six months of VETORYL® Capsules (trilostane) treatment.

Mitch had three episodes of diarrhea 5.5 months after starting therapy, which resolved within 24 hours of the owners feeding the dog a bland diet. No adjustments were made in the VETORYL Capsules treatment protocol.

Dr. Bruyette's perspective

As illustrated by this case, polyuria and polydipsia may be the only clinical signs of hyperadrenocorticism in some patients. Although Mitch had mild bilaterally symmetrical endocrine alopecia, this abnormality was subtle. If the polyuria and polydipsia had not been identified, the alopecia may not have warranted a diagnostic workup.

This case also serves as a reminder that 15% to 20% of dogs with hyperadrenocorticism may have normal ACTH stimulation test results at initial evaluation.¹ An LDDS test is the next diagnostic step for dogs that have clinical signs suggestive of hyperadrenocorticism but normal ACTH stimulation test results. However, up to 10% of dogs with hyperadrenocorticism will have a normal LDDS test result.¹ So in direct contrast to Mitch's situation, if an LDDS test is used as the initial screening test and the result is normal, perform an ACTH stimulation test.

For dogs with hyperadrenocorticism being treated with VETORYL Capsules, the target post-ACTH serum cortisol concentration is 1.45 to 9.1 µg/dl, along with well-controlled clinical signs. Mitch obtained clinical and hormonal improvement with once-daily dosing of VETORYL Capsules.

REFERENCE

1. Gilor C, Graves TK. Interpretation of laboratory tests for canine Cushing's syndrome. *Top Companion Anim Med* 2011;26(2):98-108.

This case was solicited from the prescribing veterinarian and may represent an atypical case study. Similar results may not be obtained in every case.

*The dog in the photographs is not Mitch, the dog described in this article.



Some dogs with hyperadrenocorticism may have normal ACTH stimulation test results at initial evaluation; an LDDS test is the next diagnostic step for dogs with clinical signs.

VETORYL® Capsules (trilostane) are the only FDA-approved drug indicated for the treatment of pituitary-dependent and adrenal-dependent hyperadrenocorticism (PDH and ADH) in dogs. Trilostane, the active ingredient, blocks hormone production in the adrenal cortex by competitive enzyme inhibition and is clinically effective in treating dogs with PDH and ADH; however, it does not affect tumor growth.

- The use of VETORYL Capsules is contraindicated in dogs that have demonstrated hypersensitivity to trilostane.
- Do not use VETORYL Capsules in animals with primary hepatic disease or renal insufficiency.
- Do not use in pregnant dogs. Studies conducted with trilostane in laboratory animals have shown teratogenic effects and early pregnancy loss.
- The most common adverse reactions reported are poor/reduced appetite, vomiting, lethargy/dullness, and weakness.
- Occasionally, more serious reactions, including severe depression, hemorrhagic diarrhea, collapse, hypoadrenocortical crisis or adrenal necrosis/rupture may occur, and may result in death.

Case file: HOLLY

8-year-old spayed female German shepherd weighing 33.3 kg (73.3 lb)

Patient history and initial referral findings

Holly's primary care veterinarian had diagnosed hyperadrenocorticism based on her history and clinical signs and the results of routine laboratory tests and a low-dose dexamethasone suppression test. Holly was treated for hyperadrenocorticism with trilostane (75 mg given orally once a day) obtained from a compounding pharmacy.

Six months later, Holly developed lethargy, vomiting, and abdominal distention and had markedly increased hepatic enzyme activities. The trilostane was discontinued and Holly was referred to MidWest Veterinary Specialty Hospital for an abdominal ultrasonographic examination. Peritoneal effusion secondary to a ruptured gallbladder mucocele was identified, and Holly was successfully managed with cholecystectomy and appropriate supportive critical care.

Follow-up referral evaluation

About one month after recovery from the cholecystectomy, Holly was again presented to MidWest Veterinary Specialty Hospital for evaluation of hair loss, increased panting, and polyuria and polydipsia. Holly's owners stated that she was otherwise clinically normal at home. Abnormalities identified on physical examination were patchy dorsolateral truncal alopecia with cutaneous hyperpigmentation, a pendulous abdomen, and moderate dental tartar with gingival inflammation (*Figure 1*).

The results of a serum chemistry profile revealed increased alkaline phosphatase, alanine aminotransferase, asparagine amino-



FIGURE 1. When presented, 8-year-old Holly was experiencing increased panting, polyuria, and polydipsia. She had patchy dorsolateral truncal alopecia and a pendulous abdomen.

transferase, gamma-glutamyl transferase, and creatine kinase activities; hyperbilirubinemia; and hypercholesterolemia. The complete blood count results identified leukocytosis with a mature neutrophilia and monocytosis. Urinalysis showed a urine specific gravity of 1.027, bilirubinuria (1+; reference range = negative) and trace proteinuria (< 100 mg/dl; reference range = negative). All of these findings were deemed consistent with hyperadrenocorticism.

Confirmatory test results

The results of an adrenocorticotrophic hormone (ACTH) stimulation test revealed a baseline cortisol concentration of 12.4 µg/dl (reference range = 2 to 6 µg/dl) and a one-hour post-ACTH cortisol concentration of 28.7 µg/dl (reference range = 8 to 18 µg/dl). The abnormal ACTH stimulation test results in combination with Holly's history, clinical signs, and other abnormal laboratory test

results confirmed hyperadrenocorticism.

The previous abdominal ultrasonographic examination and direct adrenal visualization at the time of exploratory laparotomy for cholecystectomy identified that both adrenal glands were normal size and shape, which is consistent with pituitary-dependent hyperadrenocorticism. Medical therapy options were discussed with the family, who elected treatment with VETORYL® Capsules (trilostane).

Treatment and follow-up

Treatment with VETORYL Capsules was begun at a dose of 3.6 mg/kg given orally once daily in the morning with food. The family was advised to keep a daily journal to document Holly's frequency of panting, water consumption, urination frequency, appetite voracity, and activity level. They were also asked to document any episodes of vomiting or diarrhea and to call with



Christopher G. Byers, DVM, DACVECC, DACVIM

Dr. Byers is Medical Director at VCA MidWest Veterinary Referral & Emergency Center and is an adjunct associate professor in the Department of Clinical Sciences at Kansas State University's College of Veterinary Medicine.

any questions or concerns. Holly's family was also advised to consult with her primary care veterinarian regarding prophylactic dental care.

Initial follow-up visits

At the two-week recheck visit, Holly's family reported reductions in her panting frequency, polydipsia, and polyuria. Her appetite was normal, and she had no episodes of vomiting or diarrhea. Holly's activity level was unchanged and still normal. A post-ACTH stimulation cortisol concentration measured 4.5 hours after administration of her VETORYL® Capsules (trilostane) dose was 1.5 µg/dl, indicating adequate inhibition of glucocorticoid production. Based on these results and the improvement in her clinical signs, the initial VETORYL Capsules dosage was continued, and Holly was scheduled for a 30-day post-treatment recheck examination.

At the subsequent visit, the family reported Holly was doing exceptionally well at home with resolution of her excessive panting, polyuria, and polydipsia. Furthermore, her hair coat was markedly improved in fullness and luster, hyperpigmentation was not evident, and her abdomen was not pendulous. A serum chemistry profile revealed that her liver enzyme activities were improved, with only an elevated gamma-glutamyl transferase activity (previously 185 U/L; this visit = 15 U/L; reference range = 0 to 14 U/L). No abnormalities were identified on a complete blood count or urinalysis. A post-ACTH stimulation cortisol concentration measured four hours after the VETORYL Capsule dose was 1.7 µg/dl, indicating adequate inhibition of glucocorticoid production. The initial VETORYL Capsules dosage was continued, and a 90-day post-treatment recheck examination was scheduled.

Holly's long-term response

At her three-, six-, and nine-month post-treatment recheck visits, Holly continued to be clinically normal (Figure 2). The ACTH stimulation tests revealed post-ACTH cortisol concentrations of 3.1 µg/dl at three months, 2.3 µg/dl at six months and 2.3 µg/dl at nine months of VETORYL Capsules treatment. Holly was treated successfully by her primary care veterinarian for a presumptive bacterial urinary tract infection seven months after starting therapy. No adjustments were made in the VETORYL Capsules treatment protocol.

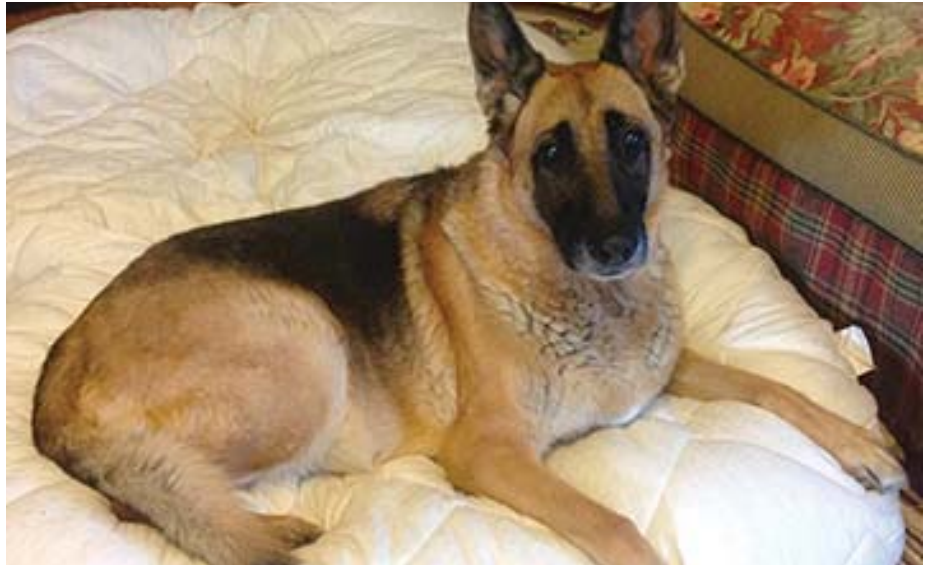

FIGURE 2. At her three-, six-, and nine-month post-treatment recheck appointments, Holly was clinically normal.

Dr. Byers' perspective

The use of VETORYL Capsules for the management of pituitary-dependent hyperadrenocorticism readily inhibits glucocorticoid production to promote resolution of common clinical signs caused by hyperadrenocorticism — most notably polyuria, polydipsia, increased panting, and hair coat changes — and biochemical derangements associated with this disease. The use of properly dosed VETORYL Capsules is strongly recommended rather than compounded trilostane to ensure maximal efficacy and safety during medical management of hyperadrenocorticism.¹

When using VETORYL Capsules, encourage families to keep a detailed journal of their dog's

daily activities, appetite, and thirst. In addition, advise owners to immediately report any possible adverse events, such as hyporexia or anorexia, vomiting, and diarrhea. Information about a patient's clinical condition is essential when interpreting post-ACTH stimulation cortisol concentrations and making recommendations for VETORYL Capsules dosage adjustments.

REFERENCE

1. Cook AK, Nieuwoudt CD, Longhofer SL. Pharmaceutical evaluation of compounded trilostane products. *J Am Anim Hosp Assoc* 2012;48:228-233.

This case was solicited from the prescribing veterinarian and may represent an atypical case study. Similar results may not be obtained in every case.

VETORYL® Capsules (trilostane) are the only FDA-approved drug indicated for the treatment of pituitary-dependent and adrenal-dependent hyperadrenocorticism (PDH and ADH) in dogs. Trilostane, the active ingredient, blocks hormone production in the adrenal cortex by competitive enzyme inhibition and is clinically effective in treating dogs with PDH and ADH; however, it does not affect tumor growth.

- The use of VETORYL Capsules is contraindicated in dogs that have demonstrated hypersensitivity to trilostane.
- Do not use VETORYL Capsules in animals with primary hepatic disease or renal insufficiency.
- Do not use in pregnant dogs. Studies conducted with trilostane in laboratory animals have shown teratogenic effects and early pregnancy loss.
- The most common adverse reactions reported are poor/reduced appetite, vomiting, lethargy/dullness, and weakness.
- Occasionally, more serious reactions, including severe depression, hemorrhagic diarrhea, collapse, hypoadrenocortical crisis or adrenal necrosis/rupture may occur, and may result in death.

Case file: LIBBY

12-year-old spayed female toy poodle weighing 5.3 lb (2.4 kg)

Patient history and initial diagnostic workup

Libby was presented to her primary care veterinarian for a dental prophylaxis. Libby also had a six-month history of panting, polyuria, polydipsia, and recurrent ear infections. Physical examination before the dental procedure revealed a swelling in Libby's perineal region, and the veterinarian subsequently diagnosed a left perineal hernia. The dental prophylaxis was rescheduled for a later date, and Libby was referred to the Mississippi State University College of Veterinary Medicine (MSU-CVM) for hernia repair.

Referral evaluation

On presentation to MSU-CVM, Libby was bright and alert. The left perineal hernia was noticeable and was easily reduced. Her abdomen appeared distended, but abdominal palpation revealed no abnormalities. The results of a serum chemistry profile revealed mild increases in alanine aminotransferase (136 U/L; reference range = 10 to 90 U/L) and alkaline phosphatase (153 U/L; reference range = 11 to 140 U/L) activities. Libby's urine specific gravity was 1.019. Based on these results and the history of panting, polyuria, polydipsia, and recurrent infections, a workup for hyperadrenocorticism was performed.

Adrenal function test results

Results of an adrenocorticotropic hormone (ACTH) stimulation test revealed a baseline cortisol concentration of 8.5 µg/dl (reference range = 1.4 to 5 µg/dl) and a one-hour post-ACTH cortisol concentration of 24.8 µg/dl (reference range = 5.5 to 20 µg/dl). These results confirmed hyperadrenocorticism.



**Todd M. Archer,
DVM, MS, DACVIM**

Dr. Archer is an associate professor of small animal internal medicine in the Department of Clinical Sciences at the Mississippi State University College of Veterinary Medicine.

*The dog in the photograph is not Libby, the dog described in this article.



Imaging

Abdominal imaging was performed to differentiate pituitary-dependent hyperadrenocorticism (PDH) from an adrenal tumor. The abdominal radiographic findings were unremarkable. Abdominal ultrasonography revealed normal-sized and symmetrical adrenal glands and no evidence of an adrenal mass. Also noted were a single hepatic lesion and a single splenic lesion, as well as a gallbladder mucocele in the early stages of development. Ultrasound-guided fine-needle aspirates of the lesions within the liver and spleen were obtained. A thoracic radiographic examination was also performed, and the findings were unremarkable.

Diagnosis

Libby's abnormal ACTH stimulation test results along with the abdominal ultrasonographic findings provided a working diagnosis of PDH.

Cytologic examination of the hepatic and splenic lesion aspirates showed mild extramedullary hematopoiesis, likely consistent with regenerative nodules. The liver aspirates also showed evidence of vacuolar degeneration, a finding consistent with hyperadrenocorticism.

Initial treatment

It was recommended that Libby receive treatment for PDH before undergoing perineal hernia repair surgery, and the owner chose medical therapy for PDH. Management of Libby's mucocele would be instituted later if needed.

Because of Libby's small size and because I start patients with hyperadrenocorticism at the low end of the recommended VETORYL® Capsules (trilostane) dose range, I prescribed 5-mg compounded trilostane capsules, given once daily at a dose of 2.1 mg/kg in an extralabel fashion. These 5-mg capsules were compounded from VETORYL Capsules at the MSU-CVM pharmacy.

Libby's owners were instructed to give Libby one 5-mg trilostane capsule orally once daily in the morning with food and to return in 14 days for a recheck and follow-up ACTH stimulation test. The owners were also instructed to watch for signs of hypoadrenocorticism (such as weakness, lethargy, vomiting, or anorexia) and to seek immediate veterinary care if she exhibited these signs.

Follow-up visits

At the two-week follow-up visit, Libby was doing better at home, with a reduction in clinical signs and no adverse reactions to trilostane. Upon questioning, the owners stated that they had been administering the trilostane capsules at night. The ACTH stimulation test to monitor dogs receiving VETORYL Capsules should be performed four to six hours after drug administration, so the owners were again instructed to administer Libby's trilostane capsules in the morning with food and to reschedule the ACTH stimulation test.

Libby was presented two weeks later for a

recheck examination. The owner reported that Libby was doing well at home. Her polydipsia and polyuria had improved slightly, and her panting had decreased markedly. On physical examination, Libby was bright and alert with a normal temperature, pulse, and respiration. Her perineal hernia was unchanged.

An ACTH stimulation test was performed four hours after trilostane administration. Libby's baseline cortisol concentration was 1.9 µg/dl and her post-ACTH cortisol concentration was 3.7 µg/dl, indicating adequate inhibition of glucocorticoid production. Measurement of Libby's serum electrolyte concentrations (recommended at the 30-day post-VETORYL® Capsules (trilostane) treatment re-examination) was inadvertently overlooked at this visit.

Libby's owners were instructed to continue to give Libby one 5-mg trilostane capsule once daily in the morning with food, to schedule surgical repair of the perineal hernia within three weeks, and to schedule a three-month post-trilostane treatment recheck examination.

Two weeks later, Libby was presented to MSU-CVM for surgical hernia repair, which was completed without complications. Libby's preanesthetic CBC and serum chemistry profile results were clinically unremarkable. Libby is scheduled to return to the internal medicine service for a three-month post-trilostane treatment re-examination.

Dr. Archer's perspective

Libby's case illustrates the need to evaluate the patient history and results of routine blood tests to help identify hyperadrenocorticism as a possible differential diagnosis. Initially, the dental prophylaxis and perineal hernia were the primary concerns in this patient, but ultimately Cushing's disease was diagnosed and treated.

An early gallbladder mucocele was identified during Libby's workup. The mucocele will be further assessed during future rechecks, with therapy instituted as indicated. In a recent study, mucocele formation was 29 times more likely in dogs with hyperadrenocorticism than in dogs without hyperadrenocorticism.¹ Although Libby did not present with clinical signs or have laboratory abnormalities consistent with a gallbladder mucocele, a mucocele should be considered in any dog with hyperadrenocorticism that presents with acute illness

VETORYL® Capsules (trilostane) are the only FDA-approved drug indicated for the treatment of pituitary-dependent and adrenal-dependent hyperadrenocorticism (PDH and ADH) in dogs. Trilostane, the active ingredient, blocks hormone production in the adrenal cortex by competitive enzyme inhibition and is clinically effective in treating dogs with PDH and ADH; however, it does not affect tumor growth.

- The use of VETORYL Capsules is contraindicated in dogs that have demonstrated hypersensitivity to trilostane.
- Do not use VETORYL Capsules in animals with primary hepatic disease or renal insufficiency.
- Do not use in pregnant dogs. Studies conducted with trilostane in laboratory animals have shown teratogenic effects and early pregnancy loss.
- The most common adverse reactions reported are poor/reduced appetite, vomiting, lethargy/dullness, and weakness.
- Occasionally, more serious reactions, including severe depression, hemorrhagic diarrhea, collapse, hypoadrenocortical crisis or adrenal necrosis/rupture may occur, and may result in death.

and evidence of hepatobiliary disease.

I prescribed compounded trilostane for Libby in an extralabel fashion because of her small size and because I prefer to start patients with hyperadrenocorticism at the low end of the labeled VETORYL Capsules dose range. Specific patients may require trilostane in strengths or forms not offered by VETORYL Capsules. If compounding cannot be avoided, trilostane can only be legally compounded using the contents of FDA-approved VETORYL Capsules as the starting material.²

In a recent study, all batches of capsules compounded from VETORYL Capsules (compounded controls) conformed to the acceptance criteria for trilostane content (90% to 105% of label claim), whereas 38% of the batches of compounded capsules purchased from compounding pharmacies failed to meet the acceptance criteria for content.³ The mean percent dissolution for compounded capsules purchased from compounding pharmacies was also lower and impurity profiles were significantly higher when compared with capsules compounded from VETORYL Capsules. This highlights the need to ensure that the compounding pharmacy you use is technically proficient and formulates compounded trilostane capsules from VETORYL Capsules.

Keep in mind that when the granules are removed from VETORYL Capsules to create a compounded trilostane drug, the drug can no longer be called VETORYL Capsules. Also, the safety, effectiveness, and stability of the com-

pounded drug become the responsibility of the prescribing veterinarian, and are not the responsibility of Dechra Veterinary Products or the compounding pharmacy.^{4,5}

In addition, Libby's case highlights the need to ensure that owners understand how to administer trilostane. The follow-up ACTH stimulation testing that is performed as part of patient monitoring during treatment with VETORYL Capsules should occur four to six hours after administration, which makes administering the drug once a day in the morning ideal.

REFERENCES

1. Mesich ML, Mayhew PD, Paek M, et al. Gall bladder mucoceles and their association with endocrinopathies in dogs: a retrospective case-control study. *J Small Anim Pract* 2009;50:630-635.
2. U.S. Food and Drug Administration. Compliance Policy Guide 7125.40. Section 608.400: Compounding of Drugs for Use in Animals. Available at <http://www.fda.gov/ICECI/ComplianceManuals/CompliancePolicyGuidanceManual/ucm074656.htm>. Accessed Sept. 30, 2013.
3. Cook AK, Nieuwoudt CD, Longhofer SL. Pharmaceutical evaluation of compounded trilostane products. *J Amer Anim Hosp Assoc* 2012;48(4):228-233.
4. U.S. Food and Drug Administration. Code of Federal Regulations Title 21. 530.13(b)(4): Rules and Provisions for Extralabel Uses of Drugs in Animals. Available at <http://www.accessdata.fda.gov/scripts/cdrh/cfdocs/cfcfr/CFRSearch.cfm?fr=530.13>. Accessed Sept. 30, 2013.
5. Spies, A. Compounding: The practice of pharmacy or a liability risk? *Drug Topics* 2002;14:36. Available at <http://drugtopics.modernmedicine.com/drug-topics/news/ce-compounding-practice-pharmacy-or-liability-risk>. Accessed Sept. 30, 2013.

This case was solicited from the prescribing veterinarian and may represent an atypical case study. Similar results may not be obtained in every case.

Case file: BOCA

8-year-old spayed female Shih Tzu weighing 14 lb (6.4 kg)

Patient history and initial diagnostic workup

Boca was presented to Parkview Veterinary Hospital for evaluation of polyuria, polydipsia, skin lesions, and signs of gastrointestinal discomfort. Boca had a previous history of intermittent gastrointestinal signs including stool that would vary from soft to liquid, inappropriate fecal elimination in the house, and vomiting. These signs had previously improved after her diet was changed to a food containing hydrolyzed protein.

Physical examination revealed pain upon abdominal palpation, borborygmi, and calcinosis cutis on the dorsal head and neck.

A serum chemistry profile showed elevated alkaline phosphatase (ALP), alanine transaminase (ALT), and gamma glutamyl transferase (GGT) activities. Boca's urine specific gravity was 1.014.

An abdominal ultrasonographic examination revealed a biliary mucocele and hepatomegaly. Boca was subsequently referred to a veterinary surgeon, and her gallbladder was removed.

Adrenal function test results

An ACTH stimulation test performed two weeks after the gallbladder surgery showed a baseline cortisol concentration of 8.1 µg/dl (reference range = 1.0 to 5.0 µg/dl) and a one-hour post-ACTH cortisol concentration of 44.5 µg/dl (reference range = 8.0 to 17.0 µg/dl). These results were consistent with a diagnosis of hyperadrenocorticism.

I discussed two medical treatment options with the owners—mitotane and VETORYL® Capsules (trilostane). I advised the owners that mitotane was not approved for use in dogs and that I had experience with using mitotane to



Boca, after treatment with VETORYL® Capsules (trilostane) and awaiting re-examination.

treat canine hyperadrenocorticism but not with VETORYL Capsules. The owners elected to treat Boca with mitotane in an extra-label fashion.

Initial treatment

After 11 days of once daily treatment with an induction dose of mitotane, Boca's baseline cortisol concentration was 1.0 µg/dl and her one-hour post-ACTH cortisol concentration was 1.1 µg/dl. Based on these results, the induction dose of mitotane was discontinued and a

twice-weekly maintenance dose of mitotane was started. A low dose of prednisone was also given on the mitotane treatment days.

After one month on the maintenance dose of mitotane with prednisone, Boca's owners reported that she had diarrhea and lethargy on the days she received mitotane. Boca's baseline cortisol concentration was 2.8 µg/dl and her one-hour post-ACTH cortisol concentration was 5.2 µg/dl. Her ALP, ALT, and GGT activities were still elevated. Boca's diarrhea



Cynthia Nichols, DVM

Dr. Nichols owns and operates Nichols Veterinary Care in Monterey, Calif.

was managed with supportive care and the prednisone and mitotane were continued at the same dosages.

After one year of treatment with mitotane and prednisone, Boca presented for evaluation of vomiting and diarrhea with tenesmus. Her ALP, ALT, and GGT activities were still elevated. An ACTH stimulation test showed a baseline cortisol concentration of 6.8 µg/dl and a one-hour post-ACTH cortisol concentration of 24.5 µg/dl.

Because Boca would again need to receive mitotane at an induction dose and she had not tolerated mitotane well to date, I recommended discontinuing treatment with mitotane and prednisone and starting treatment with VETORYL® Capsules (trilostane) one month later.

Treatment with VETORYL Capsules

The owners took time to consider their options, and Boca did not receive mitotane or prednisone for more than three months. The owners reported that Boca's water consumption seemed normal, but that her clinical signs of gastrointestinal discomfort recurred, and her calcinosis cutis began to recur as well. The return of her clinical signs and the previously elevated post-ACTH cortisol concentration provided evidence that Boca still had enough functioning adrenal tissue to warrant the use of VETORYL Capsules.

Boca was treated with VETORYL Capsules at 10 mg once daily in the morning with a meal. This commercially available capsule size provided the dose closest to the low end of the labeled dosage range of 1 to 3 mg/lb (2.2 to 6.7 mg/kg). After nine days of VETORYL Capsules treatment, an ACTH stimulation test revealed a baseline cortisol concentration of 9.1 µg/dl and a one-hour post-ACTH cortisol concentration of 14.2 µg/dl. The owners reported that Boca was doing well and experienced no diarrhea or lethargy while receiving VETORYL Capsules. Her calcinosis cutis was resolving steadily. Boca was

It can be intimidating in a complex case such as Boca's to try a new drug and treatment protocol for the first time.

continued on the same dose of VETORYL Capsules; the dose was not increased because she was doing well clinically and because of her history of sensitivity to mitotane. Boca's owners were advised to schedule a 30-day post-treatment recheck examination, and Boca's re-examination is pending (*photo, page 16*).

Dr. Nichols' perspective

Boca may have been exhibiting some atypical gastrointestinal signs of hyperadrenocorticism,¹⁻³ along with the more typical clinical signs such as polyuria, polydipsia, and calcinosis cutis. She also had a biliary mucocele, which may be more likely to occur in dogs with hyperadrenocorticism.⁴

Because Boca would have required reinduction with mitotane and had not tolerated mitotane treatment well, I tried VETORYL Cap-

sules for the first time. It can be intimidating in a complex case such as Boca's to try a new drug and treatment protocol for the first time. I have been pleased with the simplicity of this protocol to treat canine hyperadrenocorticism.

REFERENCES

1. Hess, RS, Kass PH, Shofer FS, et al. Evaluation of risk factors for fatal acute pancreatitis in dogs. *J Am Vet Med Assoc* 1999;214(1):46-51.
2. Cook AK, Breitschwerdt EB, Levine JF, et al. Risk factors associated with acute pancreatitis in dogs: 101 cases (1985-1990). *J Am Vet Med Assoc* 1993;203(5):673-679.
3. Nichols R. Concurrent illness and complications associated with canine hyperadrenocorticism. *Semin Vet Med Surg (Small Anim)* 1994;9(3):132-136.
4. Mesich ML, Mayhew PD, Paek M. Gall bladder mucoceles and their association with endocrinopathies in dogs: a retrospective case-control study. *J Small Anim Pract* 2009;50(12):630-635.

This case was solicited from the prescribing veterinarian and may represent an atypical case study. Similar results may not be obtained in every case.

VETORYL® Capsules (trilostane) are the only FDA-approved drug indicated for the treatment of pituitary-dependent and adrenal-dependent hyperadrenocorticism (PDH and ADH) in dogs. Trilostane, the active ingredient, blocks hormone production in the adrenal cortex by competitive enzyme inhibition and is clinically effective in treating dogs with PDH and ADH; however, it does not affect tumor growth.

- The use of VETORYL Capsules is contraindicated in dogs that have demonstrated hypersensitivity to trilostane.
- Do not use VETORYL Capsules in animals with primary hepatic disease or renal insufficiency.
- Do not use in pregnant dogs. Studies conducted with trilostane in laboratory animals have shown teratogenic effects and early pregnancy loss.
- The most common adverse reactions reported are poor/reduced appetite, vomiting, lethargy/dullness, and weakness.
- Occasionally, more serious reactions, including severe depression, hemorrhagic diarrhea, collapse, hypoadrenocortical crisis or adrenal necrosis/rupture may occur, and may result in death.

Case file: HOWIE

8-year-old neutered male English field spaniel weighing 72.5 lb (32.9 kg)

Patient history and initial diagnostic workup

Howie was presented to his primary care veterinarian with a six-month history of increased appetite, polyuria, and polydipsia and a two-week history of reduced activity level. A serum chemistry profile identified elevations in alanine aminotransferase and alkaline phosphatase activities and elevated triglyceride concentrations. A complete blood count identified an elevated hematocrit, thrombocytopenia, mature neutrophilia, and eosinophilia. A urinalysis was not performed.

Low-dose dexamethasone suppression test results revealed a resting cortisol concentration of 9.5 µg/dl (reference range = 1 to 5 µg/dl), with four- and eight-hour post-dexamethasone cortisol concentrations of 0.9 µg/dl and 0.9 µg/dl, respectively (reference range < 1.4 µg/dl). The results of an adrenocorticotrophic hormone (ACTH) stimulation test revealed a resting cortisol concentration of 8.6 µg/dl and a one-hour post-ACTH cortisol concentration of 21.3 µg/dl (reference range = 8 to 17 µg/dl).

The abnormal ACTH stimulation test result, in combination with Howie's clinical signs and biochemical derangements, was consistent with a diagnosis of hyperadrenocorticism. Howie was referred to MidWest Veterinary Specialty Hospital to be further evaluated.

Referral evaluation

Physical examination identified a generally dull hair coat with patchy dorsal truncal hypotrichosis, hepatomegaly, and obesity. To confirm the laboratory findings documented on

in-house analyzers by the primary care team, a serum chemistry profile was repeated and identified an alkaline phosphatase activity of 10,387 U/L (reference range = 10 to 150 U/L) and an alanine aminotransferase activity of 127 U/L (reference range = 5 to 107 U/L). A complete blood count identified a mature neutrophilia; the hematocrit and eosinophil and platelet counts were within reference ranges (the previous abnormalities identified in these three parameters may have been spurious results). The triglyceride concentration was not measured. A urinalysis identified a urine specific gravity of 1.033 with 4+ proteinuria and an inactive urine sediment.

Abdominal ultrasonography identified a diffusely hyperechoic liver with markedly rounded margins, and both adrenal glands measured approximately 0.60 cm at their widest diameter (normal range < 0.74 cm). An endogenous ACTH concentration was 16.4 pmol/L (reference range = 6.7 to 25.0 pmol/L).

Howie's physical examination findings and diagnostic test results were consistent with pituitary-dependent hyperadrenocorticism (PDH). Medical therapy options were discussed with the family, who elected treatment with VETORYL® Capsules (trilostane).

Treatment and follow-up

Treatment with VETORYL Capsules was begun at a dose of 3.6 mg/kg given orally once daily in the morning with food. The family was advised to keep a daily journal to document Howie's frequency of panting and urination, water consumption, appetite voracity, and activity level. They were also asked to document any episodes of vomiting or diarrhea and to call with any questions or concerns.

Day 14 re-evaluation

At the two-week recheck visit, the family reported that Howie had new hair growth and exhibited normal activity but had a persistence of polyuria, polydipsia, and poly-

Physical examination identified a dull hair coat with patchy dorsal truncal hypotrichosis, hepatomegaly, and obesity.

phagia. Howie's physical examination findings were unchanged from the initial presentation.

A post-ACTH stimulation cortisol concentration measured four hours after administration of the VETORYL Capsules dose was 7.0 µg/dl. Based on these results and the persistence of Howie's clinical signs, the VETORYL Capsules dosage was increased to 4.0 mg/kg, given orally once daily in the morning with food. Howie was scheduled for a recheck examination in two weeks.

Day 30 re-evaluation

At the 30-day post-treatment recheck, the owners reported that Howie had a normal energy level with continued hair regrowth and resolution of polyphagia, and decreasing polyuria and polydipsia. Physical examination identified mild weight loss (0.2 kg) and mild improvement of his dorsal truncal hypotrichosis; hepatomegaly and a dull haircoat were still present.

A post-ACTH stimulation cortisol concentration measured four hours after administration of VETORYL Capsules was 4.6 µg/dl; serum electrolytes and a follow-up CBC and urinalysis were not evaluated because of family financial constraints. Based on these results and the dog's continued improvement in or resolution of clinical signs, the VETORYL Capsules dose was not changed. Howie was scheduled for a recheck examination in one month.



Christopher G. Byers, DVM, DACVECC, DACVIM

Dr. Byers is Medical Director at VCA MidWest Veterinary Referral & Emergency Center and is an adjunct associate professor in the Department of Clinical Sciences at Kansas State University's College of Veterinary Medicine.

Day 60 re-evaluation

At the 60-day post-treatment recheck, the family reported that Howie continued to show signs of clinical improvement, including resolution of previous weight gain (current weight 69.4 lb [31.5 kg]) and resolving polyuria and polydipsia. Furthermore, his hair coat was markedly improved in fullness and luster. Howie's activity was reported to be reduced secondary to osteoarthritis diagnosed by his primary veterinary care team.

A post-ACTH stimulation cortisol concentration measured four hours after the VETORYL® Capsules (trilostane) dose was 1.4 µg/dl, and serum electrolyte concentrations were not measured because of financial constraints. The VETORYL Capsules label states that if the ACTH stimulation test is < 1.45 µg/dl and/or if electrolyte imbalances characteristic of hypoadrenocorticism (hyperkalemia and hyponatremia) are found, VETORYL Capsules should be temporarily discontinued until recurrence of clinical signs consistent with hyperadrenocorticism and test results return to normal (1.45 to 9.1 µg/dl). VETORYL Capsules may then be reintroduced at a lower dose. However, based on my clinical experience with VETORYL Capsules treatment and assessment of Howie's clinical status, the VETORYL Capsules dosage was unchanged, and a recheck examination was scheduled.

Howie's long-term response

At Howie's next recheck visit (120 days post-treatment), the family reported the dog had a well-controlled appetite, was not exhibiting polyuria or polydipsia, and his excessive panting had resolved. Howie's activity level was reportedly much improved, and multimodal analgesia had been prescribed by his primary veterinary care team for osteoarthritis. No clinically relevant physical examination changes were noted. A post-ACTH stimulation cortisol concentration measured four hours after administration of VETORYL Capsules was 0.8 µg/dl. Serum electrolyte concentrations were not measured because

VETORYL® Capsules (trilostane) are the only FDA-approved drug indicated for the treatment of pituitary-dependent and adrenal-dependent hyperadrenocorticism (PDH and ADH) in dogs. Trilostane, the active ingredient, blocks hormone production in the adrenal cortex by competitive enzyme inhibition and is clinically effective in treating dogs with PDH and ADH; however, it does not affect tumor growth.

- The use of VETORYL Capsules is contraindicated in dogs that have demonstrated hypersensitivity to trilostane.
- Do not use VETORYL Capsules in animals with primary hepatic disease or renal insufficiency.
- Do not use in pregnant dogs. Studies conducted with trilostane in laboratory animals have shown teratogenic effects and early pregnancy loss.
- The most common adverse reactions reported are poor/reduced appetite, vomiting, lethargy/dullness, and weakness.
- Occasionally, more serious reactions, including severe depression, hemorrhagic diarrhea, collapse, hypoadrenocortical crisis or adrenal necrosis/rupture may occur, and may result in death.

the owners did not authorize this testing.

Based on these results and the continued improvement or resolution of Howie's clinical signs, the VETORYL Capsules dose was reduced to 3.8 mg/kg given orally once daily in the morning with food, and Howie was scheduled for a recheck examination in 30 days. The VETORYL Capsules label states that patients should be evaluated 10 to 14 days after every dose alteration; however, that scheduling was not feasible for Howie's owners.

At the 150-day post-treatment recheck, the family reported continued improvement in Howie's hair coat quality and body weight, but expressed concerns that he was again exhibiting increased appetite, panting, thirst, and urination. His physical examination was unchanged from the previous examination. A post-ACTH stimulation cortisol concentration measured four hours after the VETORYL Capsules dose was 1.5 µg/dl, indicating adequate inhibition of glucocorticoid production. However given the reported clinical signs, the VETORYL Capsules dosage was modified to 2.0 mg/kg administered every 12 hours, and a recheck examination was scheduled.

Howie was re-evaluated two weeks after the VETORYL dosage modification. The owners reported marked improvement in the dog's excessive panting, polyuria, polydipsia, and polyphagia. Howie's activity level was

unchanged, indicating he was comfortable with his current analgesia regimen. A post-ACTH stimulation cortisol concentration measured four hours after the VETORYL Capsules dose was 4.4 µg/dl, indicating adequate inhibition of glucocorticoid production. The VETORYL Capsules dose was unchanged, and a one-month recheck examination was scheduled.

Dr. Byers' perspective

Initially Howie's endogenous ACTH (eACTH) concentration was measured in an attempt to localize his disease (PDH vs. a primary adrenal tumor). Low eACTH concentrations are expected in patients with primary functional adrenal tumors because of negative feedback inhibition. A normal or elevated eACTH concentration in a patient exhibiting clinical signs and screening test results indicative of hyperadrenocorticism is most consistent with PDH.

Appropriate monitoring of post-ACTH stimulation cortisol concentrations, serum electrolyte concentrations, and clinical signs is important in the management of patients with PDH and receiving therapy with VETORYL Capsules, as dosage modifications may be needed based on these findings.

This case was solicited from the prescribing veterinarian and may represent an atypical case study. Similar results may not be obtained in every case.

Case file: CALLIE

8-year-old spayed female Yorkshire terrier weighing 11 lb (5 kg)

History and diagnostic workup

Callie was presented to her primary care veterinarian with a three-month history of polyphagia, potbelly, mild hair coat changes, and excessive panting. She had a one-year history of urinary tract infections and urinary incontinence, which were managed medically with antibiotics and phenylpropranolamine, respectively.

A serum chemistry profile showed an alkaline phosphatase activity of 536 U/L (reference range = 12 to 127 U/L) and the results of a complete blood count revealed no abnormalities.

Adrenal function test results

Results of a low-dose dexamethasone suppression (LDDS) test showed a baseline cortisol concentration of 12.3 µg/dl (reference range = 1.0 to 6.0 µg/dl), four-hour post-dexamethasone cortisol concentration of 11.5 µg/dl (reference range < 1.5 µg/dl), and an eight-hour post-dexamethasone cortisol concentration of 8.9 µg/dl (reference range < 1.5 µg/dl), and were consistent with a diagnosis of hyperadrenocorticism. Callie was referred to Cummings School of Veterinary Medicine at Tufts University for further testing to differentiate adrenal-dependent from pituitary-dependent hyperadrenocorticism (PDH).

Referral evaluation and diagnosis

The owners presented Callie for her referral evaluation six months later. Physical examination revealed a thin truncal hair coat and abdominal distention. Callie's systolic blood pressure measurement was 190 mmHg (normal = 140 to 160 mmHg), but Callie was a very nervous patient. A urinalysis showed a specific gravity of 1.028, proteinuria (100 mg/dl), and no bacterial growth on culture. A urine protein:creatinine ratio was 0.5.

Abdominal ultrasonography showed a

mildly enlarged liver with coarse echogenicity, prominent adrenal poles bilaterally, gallbladder changes suggestive of an early mucocele, and mild bilateral renal mineralization. These findings were consistent with a diagnosis of PDH. Surgical and medical treatment options were discussed with the owner who opted for medical management with VETORYL Capsules® (trilostane).

Treatment and follow-up

Before starting treatment for PDH, Callie ruptured her right cranial cruciate ligament after jumping off furniture. She was intermittently lame, and surgery was to be scheduled after stabilization of her Cushing's disease.

Treatment for PDH was started with the smallest commercially available size of VETORYL Capsules, which at that time was 30 mg (6 mg/kg), given once daily in the morning with food. The owner was instructed to monitor Callie's water consumption, urination, appetite, and activity level and to watch for vomiting and diarrhea. The potential for progressive development of a gallbladder mucocele was also discussed with the owner, and medical management with ursodeoxycholic acid was initiated.

Initial follow-up visits

At the two-week recheck, Callie was acting normally with no change in the initial complaints apart from an unstable right stifle. An ACTH stimulation test performed four hours after VETORYL Capsules administration showed pre- and post-ACTH cortisol concentrations of 3.6 µg/dl and 3.0 µg/dl, respectively, indicating good control of cortisol production. The VETORYL Capsules dose was not changed and a 30-day post-treatment recheck was scheduled.

At the subsequent examination, the owner reported that Callie was tolerating VETORYL Capsules well but continued to exhibit panting and polyphagia. Physical examination findings were unchanged. Callie's blood pressure remained elevated and was subsequently managed with an angiotensin-converting enzyme inhibitor. An ACTH

stimulation test revealed pre- and post-ACTH cortisol concentrations of 7.2 µg/dl and 6.4 µg/dl, respectively. Because of the limited commercially available capsule sizes, the VETORYL Capsules dosage was changed to 30 mg given twice daily with food. The current VETORYL label recommendation for twice daily dosing is to increase the total daily dose by one-third to one-half and divide the total amount into two doses given 12 hours apart.

Although the VETORYL Capsules label states that patients should be evaluated 10 to 14 days after every dose alteration, that scheduling was not feasible for Callie's owners, and Callie was evaluated three weeks after the dose increase. The owners reported that Callie was doing well, her appetite had returned to normal, and she was not panting excessively. Her physical examination findings were unchanged from previous visits. Callie's ACTH stimulation test results showed pre- and post-ACTH cortisol concentrations of 7.4 µg/dl and 7.5 µg/dl, respectively, and her electrolyte concentrations were within reference ranges. A urinalysis showed a specific gravity of 1.029 and an inactive sediment. A re-examination was scheduled for 30 days later.

Callie's long-term response and follow-up

At the next re-examination (90 days after starting VETORYL Capsules treatment), the owner reported that Callie was doing well, no longer had signs of hyperadrenocorticism, and no longer required phenylpropranolamine to control incontinence. Physical examination revealed that Callie had a fuller coat. An ACTH stimulation test showed that the pre- and post-ACTH cortisol concentrations were 5.8 µg/dl and 5.6 µg/dl, respectively, and her electrolyte concentrations were within reference ranges. A urinalysis showed a specific gravity of 1.026, 30 mg/dl protein, and an inactive sediment. Callie continued to receive 30-mg VETORYL Capsules given twice daily with food. Later that month Callie underwent surgery to repair her right cranial cruciate ligament.



**Orla Mahony,
MVB, DACVIM, DECVIM**

Dr. Mahony is a clinical assistant professor at Tufts Cummings School of Veterinary Medicine.

Six months post-treatment. At the next re-examination (six months after starting VETORYL® Capsules [trilostane] treatment), physical examination showed a good hair coat, residual abdominal distention, and a stable right stifle. A serum chemistry profile showed an elevated alkaline phosphatase activity (406 U/L) and an elevated triglyceride concentration (547 mg/dl; reference range = 30 to 338 mg/dl). Electrolyte concentrations were normal. ACTH stimulation test results showed a pre- and post-ACTH cortisol concentration of 5.2 µg/dl and 4.8 µg/dl, respectively.

Nine to eleven months post-treatment. Nine months after starting VETORYL capsules, Callie became polyphagic again. Callie's physical examination findings were unchanged from her prior visit, and the owners declined serum electrolyte measurements. An ACTH stimulation test showed pre- and post-ACTH cortisol concentrations of 7.4 µg/dl and 8.2 µg/dl, respectively. Callie's dose was increased to 40 mg (10-mg VETORYL Capsules had become commercially available) given twice daily with food.

Results of ACTH stimulation tests in the following two months showed post-ACTH cortisol concentrations between 1.45 and 5 µg/dl. Physical examination findings were unremarkable, and clinical signs of Cushing's disease had resolved. Callie continued to receive VETORYL Capsules at 40 mg twice daily.

One to four years post-treatment. Eighteen months after the diagnosis of hyperadrenocorticism (12 months after starting treatment for PDH), Callie was presented to Tufts University for evaluation of acute onset of vomiting. Abnormalities identified on a serum chemistry profile were increased alkaline phosphatase (933 U/L) and alanine aminotransferase (503 U/L; reference range = 14 to 86 U/L) activities, and increased total bilirubin (1.1 mg/dl; reference range = 0.1 to 0.3 mg/dl), triglyceride (2,275 mg/dl), and cholesterol (431 mg/dl; reference range = 82 to 355 mg/dl) concentrations. Abnormalities identified on a complete blood count were a neutrophilic leukocytosis and lymphopenia. Callie's pre- and post-ACTH cortisol concentrations were 3 µg/dl and 3.6 µg/dl, respectively. Abdominal ultrasonographic examination revealed a rounded gallbladder with moderate amounts of echogenic inspissated

bile. The gallbladder wall was hyperechoic and prominent. The diagnosis was progressive gallbladder mucocele formation without rupture.

A cholecystectomy was performed and liver biopsies were obtained. Hepatic histologic examination showed cholestasis consistent with a gallbladder mucocele, and aerobic and anaerobic bacterial cultures of bile and liver revealed no growth.

Callie recovered well from surgery, and VETORYL Capsules (40 mg/kg given twice daily with food), ursodeoxycholic acid, and the angiotensin-converting enzyme inhibitor were continued 36 hours later. Her diet was changed to a low-fat dog food to help control hyperlipidemia, which persisted postoperatively.

Results of ACTH stimulation tests in the following three months showed post-ACTH cortisol concentrations between 1.45 and 5 µg/dl. Physical examination findings were unremarkable, and clinical signs of Cushing's disease had resolved. Her triglyceride concentrations fluctuated subsequently from normal to moderately elevated.

Callie continued to receive VETORYL Capsules at 40 mg twice daily for three more years and was presented to her primary care veterinarian for re-examinations.

Dr. Mahony's perspective

Callie's case highlights the increased risk of a gallbladder mucocele in dogs with hyperadrenocorticism. One study showed that gallbladder mucocele formation was 29 times more likely in dogs with hyperadrenocorticism than in dogs without hyperadrenocorticism.¹ Ideally, Callie would have had serial abdominal ultrasonographic examinations to monitor her gallbladder changes, which were mild at the time of diagnosis of hyperadrenocorticism but which progressed despite good control of hyperadrenocorticism with VETORYL Capsules and the use of ursodeoxycholic acid. Progressive mucocele development can result in gallbladder rupture, bile peritonitis, and death.

This case also illustrates that although an LDDS test has high sensitivity for the diagnosis of hyperadrenocorticism, it may not differentiate between PDH and a functional adrenal tumor. Sixty percent of dogs with PDH have suppression of the four-hour cortisol concentration below 1.5 µg/dl or exhibit cortisol suppression of less than 50% of the baseline cortisol concentration at four or eight hours after

VETORYL® Capsules (trilostane) are the only FDA-approved drug indicated for the treatment of pituitary-dependent and adrenal-dependent hyperadrenocorticism (PDH and ADH) in dogs. Trilostane, the active ingredient, blocks hormone production in the adrenal cortex by competitive enzyme inhibition and is clinically effective in treating dogs with PDH and ADH; however, it does not affect tumor growth.

- The use of VETORYL Capsules is contraindicated in dogs that have demonstrated hypersensitivity to trilostane.
- Do not use VETORYL Capsules in animals with primary hepatic disease or renal insufficiency.
- Do not use in pregnant dogs. Studies conducted with trilostane in laboratory animals have shown teratogenic effects and early pregnancy loss.
- The most common adverse reactions reported are poor/reduced appetite, vomiting, lethargy/dullness, and weakness.
- Occasionally, more serious reactions, including severe depression, hemorrhagic diarrhea, collapse, hypoadrenocortical crisis or adrenal necrosis/rupture may occur, and may result in death.

low-dose dexamethasone administration.²

Dogs with hyperadrenocorticism are prone to urinary tract infections and incontinence. Callie had no clinical signs of urinary tract infections and did not require phenylpropranolamine to manage incontinence while being treated with VETORYL Capsules.

Callie required a moderately high dose of VETORYL Capsules to control her clinical signs of hyperadrenocorticism. In many dogs, clinical signs of the disease are well controlled on doses of 2.2 mg/kg once daily, and the current recommendation is to start at the low end of the dose range and slowly increase the dose if necessary while carefully monitoring the patient's clinical signs and serum electrolyte concentrations for signs of hypoadrenocorticism or adverse reactions. The multiple capsule sizes available today permit flexible dosing.

REFERENCES

1. Mesich MLL, Mayhew PD, Paek M, et al. Gallbladder mucoceles and their association with endocrinopathies in dogs: a retrospective case-control study. *J Small Anim Pract* 2009;50(12):630-635.
2. Feldman EC, Nelson RW, Feldman MS. Use of low- and high-dose dexamethasone tests for distinguishing pituitary-dependent from adrenal tumor hyperadrenocorticism in dogs. *J Am Vet Med Assoc* 1996;209(4):772-775.

This case was solicited from the prescribing veterinarian and may represent an atypical case study. Similar results may not be obtained in every case.

DOGS WITH RECURRING PYODERMA

While hyperadrenocorticism would probably be the number one differential diagnosis in dogs with classic clinical signs—pot belly, bilateral symmetric alopecia, polyuria, and polydipsia—this diagnosis may be overlooked in patients with more subtle clinical signs. Cushing’s syndrome can be challenging to identify because of its variable clinical manifestations in our canine patients. One of the trickier clinical presentations for veterinarians to keep in mind is recurring pyoderma.

In our practice, we find that some patients with hyperadrenocorticism experience recurring skin infections, but show none of the classic physical findings usually associated with Cushing’s syndrome. Instead, the only visible manifestation of Cushing’s disease is their recurring skin infections (Figure 1).

Remember pyoderma causes

Superficial staphylococcal skin infections or superficial pyodermas are common in dogs and have many different underlying causes. However, these underlying causes can be separated into two major categories: allergy and endocrinopathy. The patient’s age can be a diagnostic clue since many allergic dogs will initially be presented at a younger age, whereas dogs with an endocrinopathy, such as hyperadrenocorticism or hypothyroidism, will be middle-aged or older when their infections develop.

For patients that were confirmed to have and were treated for superficial pyoderma that resolved but then recurred, veterinarians should try to accomplish two goals: 1) address any active infection more intensively with topical products, and 2) identify and treat the underlying cause of the infection.

Address pyoderma topically

Because there has been a dramatic worldwide increase in the incidence of methicillin-resis-

tant *Staphylococcus pseudintermedius* (MRSP) skin infections in dogs during the past five years (Figure 2),¹⁻³ it may no longer be appropriate or acceptable to simply repeatedly treat such patients with systemic antibiotics. In my experience, topical chlorhexidine works well in patients with superficial bacterial skin infections. I have found that one of the more effective topical antimicrobial formulations to add to my pyoderma therapy regimen is 4% chlorhexidine combined with TrisEDTA (TrizCHLOR™ 4 – Dechra Veterinary Products). TrizCHLOR 4 is available in shampoo, spray-on, mousse, and medicated wipe formulations, and it is indicated for support of healthy skin in animals with conditions responsive to chlorhexidine. In my practice, addressing an active superficial pyoderma topically with TrizCHLOR 4 may help resolve the infection without the use of systemic antibiotics, if the patient can be bathed several times a week and the infected area is sprayed twice daily. I also use these topicals to help reduce the recurrence of infection until the underlying cause can be identified and controlled.

Identify the underlying cause of recurring pyoderma

The most common reason dogs develop recurring pyoderma is allergic disease, such as atopic dermatitis, parasite hypersensitivity, and adverse reactions to food. Most allergic patients exhibit pruritus or skin erythema even after the infection has resolved. Examine patients carefully after the infection is cleared for erythema of the interdigital, axillary, inguinal, or pinnal regions, which could suggest a primary allergic disease. If erythema or pruritus is not observed, then screening the patient

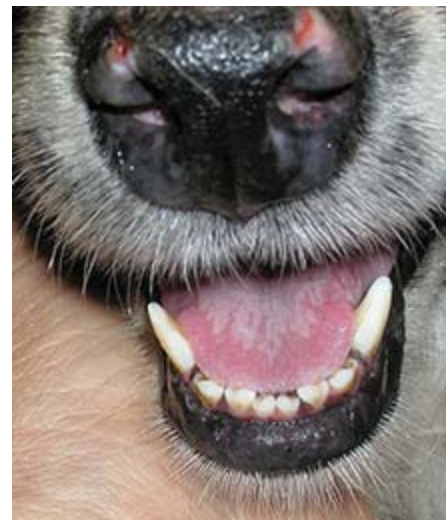

FIGURE 1. A dog with pituitary-dependent hyperadrenocorticism and secondary mucocutaneous pyoderma.

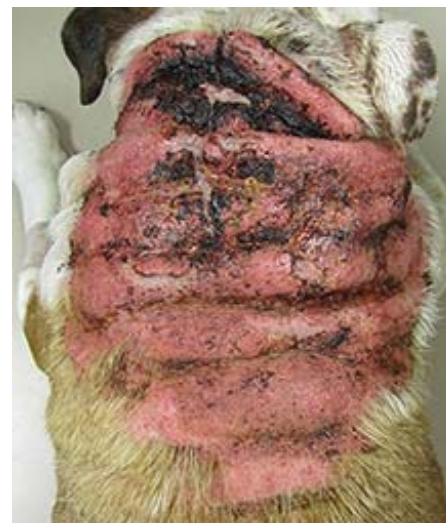

FIGURE 2. Dorsal trunk of a bulldog with a large plaque of calcinosis cutis and draining furuncles caused by methicillin-resistant *Staphylococcus pseudintermedius* superficial and deep skin infection due to pituitary-dependent hyperadrenocorticism.

for underlying endocrine diseases (hyperadrenocorticism or hypothyroidism) is indicated.

Screen for hyperadrenocorticism

A complete blood count, serum chemistry profile, and urinalysis provide important baseline data. Abnormalities in patients with hyperadrenocorticism may include neutrophilia, lymphopenia, eosinopenia, monocytosis, elevated serum alkaline phosphatase activity, hypergly-



Thomas Lewis, DVM, DACVD
Dr. Lewis' principal interests include investigating the role of allergies and their effect on the skin. Dr. Lewis is the founder of Dermatology for Animals, with clinics in multiple states.

5 QUESTIONS VETERINARIANS ASK THE DECHRA VETERINARY PRODUCTS TECHNICAL SERVICES TEAM

Diagnosing canine hyperadrenocorticism can be fairly straightforward, based on history and clinical signs, along with the results of diagnostic tests that are readily available to practitioners. Once a diagnosis of pituitary- or adrenal-dependent hyperadrenocorticism is made, VETORYL® Capsules (trilostane) are the only FDA-approved drug indicated for medical treatment of either condition. VETORYL Capsules are backed by a company with a veterinary technical services team ready to answer your questions.

In this case file, the Dechra Veterinary Products Technical Services Team answers five questions they are frequently asked about canine hyperadrenocorticism and VETORYL Capsules. When you identify canine Cushing's cases and you have questions about this treatment, contact the team who wants to help you successfully manage your patients.



Q: What is the recommended monitoring protocol, and what information should be obtained from the owner at each recheck appointment?

A: Ten to 14 days after starting VETORYL® Capsules (trilostane), re-examine the dog and perform an adrenocorticotrophic hormone (ACTH) stimulation test four to six hours after VETORYL Capsules have been administered with food. Re-examine the dog at 30 days and 90 days after beginning VETORYL Capsules, and every three months thereafter. At a minimum, this monitoring should include a thorough history and physical examination, ACTH stimulation test (conducted four to six hours after VETORYL Capsules administration, with food), and serum biochemical tests (with particular attention paid to electrolytes and renal and hepatic function). Before each ACTH stimulation test is performed, be sure to confirm that the owner gave the VETORYL Capsules that morning, and that the drug was given with a small amount of food.

We cannot overemphasize the importance of talking with the owner at each recheck appointment about how the dog is doing at home. Specifically, ask:

- Are the clinical signs of hyperadrenocorticism well controlled in your dog?
- Does your dog exhibit any new signs or conditions of concern to you?

This information is critical when interpreting the results of the ACTH stimulation and other biochemical tests. Dechra Veterinary Products encourages veterinarians to contact the Veterinary Technical Services Team if assistance is needed in interpreting test results.



Q: What sizes of VETORYL® Capsules (trilostane) are available, and is an exact dose required when starting treatment for canine hyperadrenocorticism?

A: VETORYL Capsules are available in 5, 10, 30, 60, and 120 mg sizes. The starting dose for the treatment of hyperadrenocorticism in dogs is 1.0 to 3.0 mg/lb (2.2 to 6.7 mg/kg) once a day, based on body weight and capsule size. VETORYL Capsules should always

be administered with food to ensure maximum serum levels and, thus, efficacy. Dechra Veterinary Products recommends using the lowest effective dose consistent with individual response; round the dose down if the calculated amount is between available capsule sizes and assess the patient's response to that dose in 10 to 14 days.

VETORYL® Capsules (trilostane) are the only FDA-approved drug indicated for the treatment of pituitary-dependent and adrenal-dependent hyperadrenocorticism (PDH and ADH) in dogs. Trilostane, the active ingredient, blocks hormone production in the adrenal cortex by competitive enzyme inhibition and is clinically effective in treating dogs with PDH and ADH; however, it does not affect tumor growth.

- The use of VETORYL Capsules is contraindicated in dogs that have demonstrated hypersensitivity to trilostane.
- Do not use VETORYL Capsules in animals with primary hepatic disease or renal insufficiency.
- Do not use in pregnant dogs. Studies conducted with trilostane in laboratory animals have shown teratogenic effects and early pregnancy loss.
- The most common adverse reactions reported are poor/reduced appetite, vomiting, lethargy/dullness, and weakness.
- Occasionally, more serious reactions, including severe depression, hemorrhagic diarrhea, collapse, hypoadrenocortical crisis or adrenal necrosis/rupture may occur, and may result in death.



Q: Should dogs that have test results consistent with a diagnosis of hyperadrenocorticism but no compatible clinical signs be treated?

A: The decision to treat canine hyperadrenocorticism must first be based on history and physical

examination findings suggestive of the disease. The results of a serum biochemistry panel, CBC, urinalysis, and urine protein:creatinine ratio can support but not confirm a diagnosis of hyperadrenocorticism.

Endocrine function tests (such as the low-dose dexamethasone suppression test and/or ACTH stimulation tests) should be performed when a patient exhibits clinical signs consistent with hyperadrenocorticism. None of the tests used to evaluate cortisol concentrations have 100% sensitivity or specificity; to avoid false-positive test results, the veterinarian should have a high degree of suspicion that the patient in question may have hyperadrenocorticism and has no other condition that could cause a stress-related increase in cortisol concentration. Dechra Veterinary Products does not recommend treating hyperadrenocorticism in patients with suggestive diagnostic test results but no compatible clinical signs. Likewise, patients with clinical signs suggestive of hyperadrenocorticism (bilateral alopecia, weight gain, pot-bellied appearance, etc.) should not be treated if endocrine function tests do not confirm the disease.



Q: Are compounded trilostane preparations the same product as VETORYL® Capsules (trilostane)?

A: Compounded trilostane preparations are not the same as the FDA-approved product, VETORYL Capsules. It is recognized that reformulation of VETORYL

Capsules is necessary when specific patients require trilostane in dosage strengths and/or forms that are not commercially available. FDA regulations do not permit compounding of animal products from bulk active ingredients. If you need a different strength or form of trilostane for a patient, ask that the pharmacist only compound to your specifications using the FDA-approved contents in VETORYL Capsules as the active ingredient for your prescription. This ensures your patient will at least receive a medication containing an active ingredient that has undergone FDA scrutiny for consistency, quality and efficacy.

In addition to the concern about the active ingredients in compounded medications, other variables can affect a patient's response and outcome when using compounded medications. A recent study evaluating 96 batches of compounded trilostane products purchased from eight compounding pharmacies found that the average percentage label claim for each batch ranged from 39% to 152.6%.¹ Thus, patients could be severely underdosed or overdosed when receiving these compounded preparations. Additionally, 20% of the batches analyzed did not meet the dissolution criteria; thus, patients receiving these compounded preparations may not be able to absorb the drug from their gut because the formulation is not properly dissolving after ingestion. In conclusion, the study's authors stated, "Compounded trilostane products should be used with caution as they may jeopardize the management of dogs with [hyperadrenocorticism] and potentially impact patient safety."¹



Q: What resources are available from Dechra Veterinary Products to help veterinarians and their teams successfully manage canine hyperadrenocorticism?

A: Many! Client brochures, monitoring forms, algorithms, and team training and continuing education modules are available to clinics free of charge (www.dechra-us.com/ce). (Many of the resources can be downloaded from the Dechra website (www.dechra-us.com) or can be obtained through your local Dechra Veterinary Products sales manager.

Furthermore, Dechra Veterinary Products has a staff of in-house registered veterinary technicians, veterinarians, and field-based veterinarians who are available for case consultations and for reporting suspected adverse events. **The Dechra Veterinary Technical Services Team can be reached at this toll-free phone number: 866-933-2472.**

REFERENCE

1. Cook AK, Nieuwoudt CD, Longhofer SL. Pharmaceutical evaluation of compounded trilostane products. *J Am Anim Hosp Assoc* 2012; 48:228-233.

24-Hour Veterinary Technical Support:
(866) 933-2472, support@dechra.com
www.dechra-us.com

YOUR VETERINARY TEAM'S ROLE IN IDENTIFYING DOGS WITH HYPERADRENOCORTICISM

Every day, each member of your veterinary team plays an integral role in helping pets receive regular preventive care, identifying pets that need further veterinary evaluation, and ensuring patients receive appropriate follow-up care. When your technicians and other team members are well trained, they can help keep clients informed about signs of illness in their pets so diagnoses can be reached earlier and treatments initiated sooner.

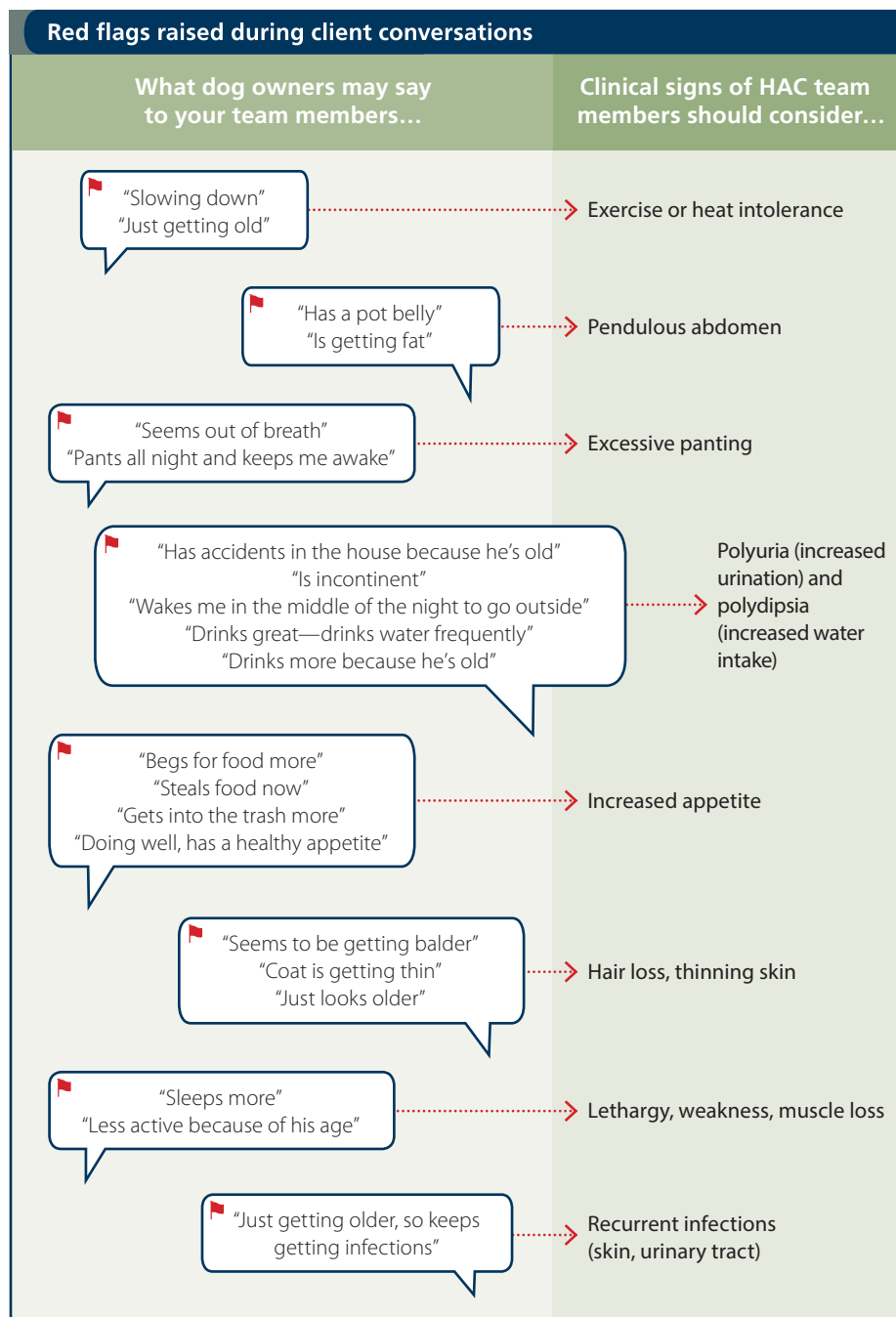
Teach your team about Cushing's

Educating clients about the signs of disease in older pets is especially important, because clients often attribute clinical signs to "normal" aging, and their pets' health may in fact be deteriorating. For example, pet owners may misinterpret some clinical signs of hyperadrenocorticism (HAC, also known as Cushing's syndrome) such as lethargy and increased urination and drinking as normal, age-related changes. Therefore, team members should understand HAC so they are comfortable communicating with clients about identifying affected pets.

This article reviews basic information about canine HAC that team members should know to help veterinarians at the practice identify potential Cushing's patients. Your team should understand the different types of HAC (see boxed text "What is hyperadrenocorticism?" on page 27), be aware of client comments that signal potential clinical signs of the disease, and help reinforce your message to clients about why multiple diagnostic tests may be needed.

Normal aging or "red flags?"

Your practice should already be educating clients about the importance of senior wellness examinations and diagnostic senior testing, which will



uncover underlying illnesses in older dogs. The clinical signs of HAC and many other illnesses can develop slowly, and many owners may simply chalk them up to normal aging. This is where you need your team to be your eyes and ears.

Your technicians and receptionists should listen carefully when clients report signs of aging in their pets, and use their expertise to

help identify these signs as initial "red flags" for the veterinarian. (See boxed text "Red flags raised during client conversations.") These signs can often have a profound effect on quality of life for the pet and of the owner.

Your team members are often the first to realize there may be a problem and should take the opportunity to engage owners in a conversation

What is hyperadrenocorticism?

Hyperadrenocorticism is a common endocrine disease in middle-aged to older dogs and results from overproduction of cortisol, a hormone that helps the body respond to stress. There are two naturally occurring forms of the disease: *pituitary-dependent hyperadrenocorticism* (PDH) and *adrenal-dependent hyperadrenocorticism* (ADH). In PDH, the pituitary gland overproduces adrenocorticotropic hormone (ACTH), which in turn stimulates excess cortisol release from the adrenal glands. ADH results from excess cortisol production by a tumor on one, or rarely, both of the adrenal glands. PDH accounts for 80% to 85% of HAC cases, and ADH accounts for 15% to 20% of cases.

Clinical signs of hyperadrenocorticism can also arise as a result of long-term administration of high doses of corticosteroid drugs. This is called *iatrogenic hyperadrenocorticism*, and, if it occurs, the corticosteroid should be discontinued. This article focuses on PDH and ADH.

about their pet's behavior at home. If owners say that their dog is fine, that he's just acting old, a team member should inquire further about what owners mean by this. Technicians can start this conversation and help set the stage for veterinarians to get owner approval for diagnostic testing.

Explaining initial tests

For pets with clinical signs and physical examination findings suggestive of HAC, team members should know that simple blood and urine tests will be the first step in the diagnostic plan. These baseline tests — a complete blood count, a serum chemistry profile, and a urinalysis — are usually components of senior wellness testing. Certain abnormal results (such as changes in liver enzyme activities, cholesterol or triglyceride concentrations, blood cell counts, and urine concentration) may signal the need for more diagnostic tests to identify HAC.

If the veterinarian suspects HAC based on the pet's clinical signs and baseline test results, then more specific testing is required. Your team can help alleviate apprehensions about testing by educating owners about these tests. They can help explain in plain language what information the results may yield. It is also important for clients to be told that there is not one simple test to confirm the diagnosis of HAC; multiple tests may be required. (See Table.)

Explaining tests to distinguish PDH from ADH

Once a diagnosis of HAC has been made, team members can reinforce your message to clients that it is important to determine if the patient has pituitary-dependent (PDH) or adrenal-dependent hyperadrenocorticism (ADH) because this affects a patient's prognosis and treatment planning. Patients with ADH may have malignant tumors on the affected adrenal gland, which may invade local vital structures. In some cases, surgery to remove the affected gland is recommended.

If the initial diagnostic test results do not differentiate between PDH and ADH, then additional tests may be needed. These include abdominal ultrasonography to evaluate the adrenal glands; a high-dose dexamethasone suppression test, which is similar to the LDDS test but

uses a higher dose of dexamethasone to assess cortisol suppression; or a computed tomography scan (CT-Scan) or magnetic resonance imaging (MRI) to evaluate the pituitary gland.

Your eyes and ears

Your team members are your adjunct eyes and ears when a client first arrives at your practice. They spend the majority of their time communicating with all your clients, in person and on the phone or via email or social media. And the veterinarian's message carries much more weight when it is consistently and repeatedly

delivered by every person the client encounters at your practice.

The veterinary team can be instrumental in identifying those dogs in which signs of old age are attributable to HAC. Hyperadrenocorticism is a complex disease process, but successful management is possible with the help of a dedicated veterinary team.

The next Canine Cushing's Case Files article will continue with a discussion of the team's role in the treatment and monitoring of dogs with HAC and direct you to readymade team training and client education resources for your practice.

TABLE Common initial tests to help identify canine hyperadrenocorticism*

Test	What It Does	What It Means	Test Requirements
Urine cortisol: creatinine ratio (UCCR)	Measures the amount of cortisol in the urine compared to creatinine	Abnormal test result = further testing needed Normal test result = 95% certainty that the dog does <i>not</i> have HAC	A single urine sample that the owner brings from home
ACTH stimulation test	Measures the ability of the adrenal glands to produce cortisol in response to an injection of ACTH	Dogs with HAC are expected to have an exaggerated cortisol response Test results do not differentiate between ADH and PDH	Two blood samples, collected one hour apart; before and after administration of synthetic ACTH
Low-dose dexamethasone suppression (LDDS) test	Measures the ability of the pituitary gland to suppress ACTH release and thus cortisol production from the adrenal glands in response to an injection of dexamethasone	Dogs with HAC are expected to show minimal or no suppression of cortisol Can be used to confirm PDH in 60% of cases	Three blood samples (baseline, then four and eight hours after administration of dexamethasone)

*Consult your diagnostic laboratory for testing requirements and sample submission instructions.

YOUR VETERINARY TEAM'S ROLE IN TREATING AND MONITORING DOGS WITH HYPERADRENOCORTICISM

Veterinary team members are instrumental in communicating with your clients — during visits, on the phone, and through email and social media. Well-trained technicians and other team members can help reinforce veterinarians' messages to clients about signs of illness in pets, the advantages of early disease recognition and treatment, and the importance of follow-up care. Team members should understand hyperadrenocorticism, a common endocrine disease in middle-aged to older dogs, so they are comfortable communicating with clients who have pets that are affected.

The previous Canine Cushing's Case Files article (pages 26 to 27) reviewed what team members should know about canine hyperadrenocorticism (HAC, also known as Cushing's syndrome) to help veterinarians identify potential Cushing's patients. It also reviewed the diagnostic procedures that are needed to reach a diagnosis of HAC and the team's role in helping to explain the tests to clients. This article focuses on what team members should know about HAC to help veterinarians successfully treat and monitor dogs with this disease.

Your team supports treatment

Once canine HAC has been diagnosed, team members can reinforce the veterinarian's mes-

sages to clients about the importance of treatment. If left untreated, the clinical signs will progress, and HAC increases a dog's risk of developing serious problems such as chronic infections of the urinary tract, skin, and ears; diabetes; thromboembolic events; proteinuria; and hypertension. The treatment goal is to maintain a good quality of life by alleviating clinical signs and secondary medical conditions.

Teach your team about treatment options for canine HAC. VETORYL® Capsules (trilostane) are the only FDA-approved treatment for both pituitary-dependent hyperadrenocorticism (PDH) and adrenal-dependent hyperadrenocorticism (ADH) in dogs. The active ingredient in VETORYL Capsules — trilostane — blocks an enzyme in the cortisol production pathway, which decreases cortisol in the body and reduces clinical signs. VETORYL Capsules are clinically effective in treating dogs with PDH and ADH; the drug does not, however, affect tumor growth.

Your team members can also share success stories with clients about other patients with HAC that have been treated at your practice. Clients like to know what to expect from treatment and appreciate hearing about other pets that are being successfully managed.

Your team supports monitoring

If patient management is to be successful, your team should reinforce your instructions to clients about VETORYL Capsules administration and the follow-up visits needed to assess their dogs' responses. Team members can reinforce the veterinarian's message that HAC is a disease that is managed rather than cured, and that dogs with HAC are treated for life and need to be monitored regularly.

Team members should also reiterate that occasionally a dog's dose of VETORYL Capsules might need to be increased, decreased, or temporarily discontinued to ensure effective treatment without side effects of hypocortisolemia. The need for such dose adjustments can only be determined through regular rechecks that include a physical examination and blood tests. Pet owners must understand these points to achieve successful treatment outcomes.

Before treatment begins, team members can suggest that either the pet owner or the clinic obtain pretreatment photos. Because a treated dog's physical improvements may take a few weeks to months to see, photos can help document response to treatment. And with an owner's consent, the photos may be used to show other clients when the team is sharing successful treatment stories.

Day 1 of treatment

Team members should reiterate the veterinarian's instructions to clients about how to give VETORYL Capsules. The drug is given once a day in the morning, and it should always be given with food to enhance drug absorption. The team should also be sure the client understands what changes to watch for in the pet at home.

Because VETORYL Capsules act by decreasing cortisol in the body, a patient may exhibit signs of hypocortisolemia, or too little cortisol, so team members must also reinforce the veterinarian's instructions to clients about what to watch for at home. Signs of hypocortisolemia include vomiting, diarrhea, lethargy/

VETORYL® Capsules (trilostane) are the only FDA-approved drug indicated for the treatment of pituitary-dependent and adrenal-dependent hyperadrenocorticism (PDH and ADH) in dogs. Trilostane, the active ingredient, blocks hormone production in the adrenal cortex by competitive enzyme inhibition and is clinically effective in treating dogs with PDH and ADH; however, it does not affect tumor growth.

- The use of VETORYL Capsules is contraindicated in dogs that have demonstrated hypersensitivity to trilostane.
- Do not use VETORYL Capsules in animals with primary hepatic disease or renal insufficiency.
- Do not use in pregnant dogs. Studies conducted with trilostane in laboratory animals have shown teratogenic effects and early pregnancy loss.
- The most common adverse reactions reported are poor/reduced appetite, vomiting, lethargy/dullness, and weakness.
- Occasionally, more serious reactions, including severe depression, hemorrhagic diarrhea, collapse, hypoadrenocortical crisis or adrenal necrosis/rupture may occur, and may result in death.

collapse, and loss of appetite.

Before the client leaves the clinic, a team member should schedule a recheck examination for 10 to 14 days after beginning VETORYL® Capsules (trilostane) treatment. Team members can reinforce the veterinarian's instructions that each recheck visit will include a history, a physical examination, electrolyte concentration measurements, and an adrenocorticotropic hormone (ACTH) stimulation test.

Day 2 or 3

Two or three days after starting treatment, a team member should call the client to follow up and ask specific questions. Good questions to ask include:

- "Do you have any difficulty giving the medication?"
- "Are you giving the drug with food?"
- "Has the dog vomited or had any diarrhea?"
- "Have you noticed any changes in your dog's appetite?"
- "Have there been any changes in the dog's activity level?"
- "Do you have any questions for me or for the doctor?"

Team members should immediately report any improvement or worsening in clinical signs to the veterinarian and document the discussion in the dog's medical record.

Day 9 to 13

The day before the first recheck appointment, a team member should call the client with a reminder that VETORYL Capsules should always be given with food, even on the day of testing. Furthermore, the client should be told that timing of the ACTH stimulation test is important; the test needs to be done four to six hours after the dog is given VETORYL Capsules in the morning because maximum cortisol suppression occurs during that time. Thus, the team member should stress that the pet needs to be in the hospital and ready for blood testing at the appropriate time.

Day 10 to 14

The 10- to 14-day recheck visit includes a history, physical examination, re-evaluation of the dog's electrolyte concentrations, and an ACTH stimulation test. Before each ACTH stimulation test is performed, team members should confirm that the owner gave the VETORYL Capsules to the dog that morning, with food. If the owner did

Readymade Tools for Training Your Team and Educating Clients

There is no need to reinvent the wheel when it comes to training your team about canine hyperadrenocorticism. Help is just a few clicks or a call away.

- Dechra Academy — www.dechra-us.com/ce
- Information about VETORYL® Capsules (trilostane) and canine hyperadrenocorticism — www.dechra-us.com
- Dechra Veterinary Technical Services Team — toll-free phone number: **866-933-2472**
- Dechra Veterinary Products client educational materials, including a Cushing's syndrome client brochure and a VETORYL Capsules Monitoring Form
- Dechra Customer Support — **866-683-0660**

not do this, the recheck should be rescheduled. Team members can ask clients to complete a "VETORYL Capsules Monitoring Form" (see boxed text "Readymade Tools for Training Your Team and Educating Clients") when clients present or drop off their dogs at the clinic for rechecks.

Each recheck visit allows team members and the veterinarian to talk with owners about how the pet is doing at home. Within two to four weeks of the start of treatment, the owners should begin seeing improvements in their dogs' clinical signs — increased energy levels, more normal water and food intake, and fewer accidents in the house or less frequent requests to go outside. Improvements in a dog's coat and skin will take three to nine months.

Team members can again help reinforce the veterinarian's message that a dog with HAC requires long-term treatment and routine monitoring. A need for a dosage change can only be determined by the veterinarian performing regularly scheduled physical examinations and diagnostic tests, along with a clear understanding of the clinical picture of how the dog is doing at home. Therefore, your team will be important partners with clients to ensure the dog is monitored carefully.

Before the client leaves, a team member should again schedule a recheck examina-

tion for the appropriate time — either 10 to 14 days after any VETORYL Capsules dosage change, or if the VETORYL Capsules dose is not changed, the recheck is scheduled for 30 days after beginning VETORYL Capsules.

Your veterinary team can help remind owners of the required follow-up visits by creating a recheck calendar. They can also schedule periodic phone calls to the client to see how the dog is doing at home. Furthermore, everyone on your team needs to emphasize that the pet should return immediately to the practice any time the dog becomes ill or if signs of HAC recur.

Four weeks and beyond

Once an optimum dose of VETORYL Capsules has been reached, dogs need to be re-evaluated at regularly scheduled recheck visits at 30 days, 90 days, and every three months thereafter, OR 10 to 14 days after any change in the dose of VETORYL Capsules.

The day before each recheck appointment, team members should call clients to remind them that VETORYL Capsules should always be given with food, even on the day of testing, and that the ACTH stimulation test needs to be done four to six hours after the dog is given VETORYL Capsules.

Listening to clients is a key component of successful VETORYL Capsules treatment. Technicians and receptionists have prime opportunities to help veterinarians assess the health of pets receiving VETORYL Capsules. Team members are the veterinarian's frontline eyes and ears, and at each recheck visit, a team member should specifically ask clients

- "Do you feel like your dog's previous clinical signs are well-controlled?"
- "Has your dog exhibited any new signs or conditions that concern you?"

Team members should report the answers to the veterinarian and should know that any signs such as vomiting, diarrhea, lethargy, or anorexia must be investigated.

Educate, empower, and motivate clients

Keeping owners educated, empowered, and motivated will help make treatment and monitoring of dogs with HAC more rewarding and support long-term success. Hyperadrenocorticism is a complex disease process, but successful management is possible with the help of a dedicated veterinary team.

THE ECONOMICS OF MANAGING HYPERADRENOCORTICISM IN DOGS

Most veterinary practice owners and managers know the amount clients spend per clinic visit and are familiar with the alphabet soup describing such transactions: Average Transaction Fee (ATF), Average Charge per Transaction (ACT), Average Transaction Charge (ATC), Average Doctor Transaction (ADT), and numerous others. These metrics — and their trends over time — reveal the health of your business. On the other hand, practices rarely examine the financial or economic impact of a particular condition or disease. We are trained to think in terms of transactions rather than considering a bigger picture. However, an underestimated financial benefit exists for any practice that produces satisfied clients who have pets with well-controlled diseases that live longer lives. These clients have a renewed trust in and loyalty to the practice and are more likely to return there for their pet's other wellness and medical needs.

The impact of managing a chronic disease

Consider the impact that management of just one common chronic disease can have on your practice's bottom line. How many canine patients with hyperadrenocorticism did you identify and treat in the last 12 months? What's the incremental gross and net income from treating and monitoring a dog with hyperadrenocorticism in the 12 months after detection, and how much impact does your pricing have on a client's ability and willingness to treat the disease?

Cushing's disease is a chronic illness that is not cured, but rather managed throughout a pet's life. What's the annual financial impact of managing patients with Cushing's syndrome on your practice? What's the long-term benefit to your practice of skillfully managing a dog with Cushing's disease and having the owners happy that their dog's clinical signs have resolved?

A year in the life of Riley

Consider a case example such as Riley,* a 12-year-old spayed female beagle that weighs 27 lb (12.3 kg). Her owners have historically taken good care of Riley and followed their longtime veterinarian's advice. Riley presented with common clinical signs of canine hyperadrenocorticism — polyuria and polydipsia, polyphagia, alopecia, and a pendulous abdomen.

Diagnosing canine hyperadrenocorticism can be fairly straightforward based on a dog's history, clinical signs, and results of readily available diagnostic tests (see the previous *Canine Cushing's Case Files* on pages 6 to 21). Examination and screening for other concurrent disease processes is also indicated.

Once the diagnosis is confirmed, VETORYL® Capsules (trilostane), the



Fritz Wood, CPA, CFP

Mr. Wood is a certified public accountant and a certified financial planner who consults with veterinarians and the veterinary industry. Mr. Wood has served on the Board of Directors of the American Veterinary Medical Foundation and on the Pricing Subcommittee of the National Commission on Veterinary Economic Issues.

*Riley is not an actual patient; this case example is provided for illustrative purposes only.

TABLE 1

Initial diagnostic test and treatment costs*		
	July 3	
	Clinic Cost	Client Cost
Comprehensive physical examination		\$50
Complete blood count	\$30	\$60
Serum chemistry profile (including electrolytes)	\$60	\$120
ACTH stimulation test **	\$70	\$140
Low-dose dexamethasone suppression test**	\$65	\$130
Urinalysis	\$20	\$40
Urine cortisol:creatinine ratio	\$75	\$150
VETORYL Capsules 30 mg (15-day supply)	\$18.25	\$36.50
Total estimated client cost***		\$726.50

* Actual costs will vary.

** Both tests may not be required.

*** Additional discriminatory tests may be performed (e.g. high-dose dexamethasone suppression test, endogenous ACTH measurement, abdominal ultrasonography), but are not included in this example because the LDDS test results indicated pituitary-dependent hyperadrenocorticism.

only FDA-approved drug indicated for medical treatment of both pituitary- and adrenal-dependent hyperadrenocorticism in dogs, can be prescribed.

Initial diagnostic test and treatment fees

Riley's evaluation and test results confirmed hyperadrenocorticism. *Table 1* lists the fees associated with Riley's diagnostic workup and her initial treatment with VETORYL Capsules.

Monitoring fees

After 10 to 14 days of treatment with VETORYL Capsules, a physical examination and adrenocorticotropic hormone (ACTH) stimulation test should be performed. Once an optimum dose of VETORYL Capsules has been reached, the dog should be re-examined at 30 days, 90 days, and then every three months thereafter OR 10 to 14 days after any change in the dose of VETORYL Capsules. This diagnostic and monitoring plan has long-term benefits not only for the patient, but also for a practice's finances.

Table 2 (on page 31) lists some of the fees associated with monitoring Riley while she receives VETORYL Capsules treatment from Day 14 through two years and beyond. With quarterly visits, the owners bond with the practice and develop a good rapport and strong relationship with the veterinary team.

Consider reducing markup

As price decreases, quantity consumed generally increases. Thus for patients with chronic diseases such as hyperadrenocorticism, consider that a typical practice markup on charges may not be required. In Riley's case example, a practice's annual out-of-pocket cost (without

production-based doctor compensation) in Year 2 and beyond is \$958 (\$239.50 x 4), and the client cost is \$2,056 (Table 2). Therefore, the profit margin per dog is 53.4% $([\$2,056 - \$958]/\$2,056)$.

A greater number of clients may be able to follow through with their pets' long-term treatment and monitoring if the costs were lower. For example, if the markup on VETORYL® Capsules (trilostane) was reduced (to that similar to the markup [45%] on a therapeutic diet for a patient with a chronic condition), and if the markup on diagnostic tests was similarly reduced, consider the costs listed in Table 3.

Table 3 shows that a practice could offer savings for clients with pets that have chronic disease and still receive an acceptable gross income and net profit. Some clients would be able to treat their dogs at the annual cost of \$2,056, but many more clients should be able and willing to treat at \$1,528 per year.

Each practice will have a specific pricing structure, which results in a given volume that maximizes profit. That topic is beyond the scope of this article, but pricing flexibility in chronic disease management is worth considering, as illustrated here with canine Cushing's syndrome. Keep in mind that a 100%, 200%, or 300% markup on drugs and diagnostic tests times zero (i.e., no pet owner is willing to purchase) is zero.

Package pricing options

Consider additional options for patient care and improving profits in your practice when managing dogs with Cushing's syndrome. Once a patient's clinical signs are well controlled, offering a discounted wellness plan that includes charges for the necessary chronic disease management follow-up appointments, laboratory work, and supply of VETORYL Capsules may improve client participation. A package pricing structure might increase the number of clients willing to continue treatment and monitoring. Veterinarians already commonly use package pricing for new puppy visits, preventive care, and preanesthetic screenings. By packaging these goods and services and ensuring a commitment early, you are more likely to gain owner compliance, thereby improving both patient wellbeing and practice revenue.

Good for patients and the practice bottom line

Clearly, diagnosing and treating canine Cushing's syndrome is an investment for clients and practices. Fortunately, reducing or eliminating clinical signs of chronic disease enhances the quality of life for both the dog and its owner. Managing canine Cushing's syndrome with VETORYL Capsules is not only good medicine, but it also contributes handsomely to the gross and net income of the practice. You will be seeing these patients for monitoring appointments and all of their wellness and health care needs for years to come. Furthermore, the pet owner now has a success story to share with other potential clients.

In order to help more pets and pet owners, while still increasing your gross and net income, consider flexibility in your pricing structure for patients that require long-term disease management. When you identify canine Cushing's syndrome cases and you have questions about treatment, you can contact the Dechra Veterinary Products Technical Services Team (at 866-933-2472) for assistance in successfully managing these patients.

TABLE 2

Treatment and monitoring costs (standard markup)				
	July 16: 14 days of VETORYL Capsules treatment		August 1: 30 days of VETORYL Capsules treatment	
	Clinic Cost	Client Cost	Clinic Cost	Client Cost
Recheck physical examination		\$35		\$35
Serum chemistry profile (including electrolytes)	\$60	\$120	\$60	\$120
ACTH stimulation test	\$70	\$140	\$70	\$140
VETORYL Capsules 30 mg	\$18.25 (15-day supply)	\$36.50	\$109.50 (90-day supply)	\$219
Total estimated cost at re-examinations	\$148.25	\$331.50	\$239.50	\$514

- **Total estimated client cost every three months thereafter:**
 - November 1 \$514
 - February 1 \$514
 - May 1 \$514
- **Year 1 total client cost (including initial workup) \$3,114**
- **Year 2 total client cost, and every year thereafter \$2,056**

This illustration excludes incremental ancillary fees that would likely occur throughout Riley's treatment.

TABLE 3

Treatment and monitoring costs (reduced markup)		
	Clinic Cost	Client Cost
Recheck exam		\$35
Serum chemistry profile (including electrolytes)	\$60	\$87
ACTH stimulation test	\$70	\$101
VETORYL Capsules (90-day supply)	\$109.50	\$159
• Total estimated cost to the client at the four-week recheck – and every three months thereafter \$382		
• Client savings at four-week recheck \$132		
• Annual client cost \$1,528		
• Annual client savings \$528		
• Annual profit margin per dog 37.3% $([\\$1,528 - \\$958]/\\$1,528)$		

VETORYL® Capsules (trilostane) are the only FDA-approved drug indicated for the treatment of pituitary-dependent and adrenal-dependent hyperadrenocorticism (PDH and ADH) in dogs. Trilostane, the active ingredient, blocks hormone production in the adrenal cortex by competitive enzyme inhibition and is clinically effective in treating dogs with PDH and ADH; however, it does not affect tumor growth.

- The use of VETORYL Capsules is contraindicated in dogs that have demonstrated hypersensitivity to trilostane.
- Do not use VETORYL Capsules in animals with primary hepatic disease or renal insufficiency.
- Do not use in pregnant dogs. Studies conducted with trilostane in laboratory animals have shown teratogenic effects and early pregnancy loss.
- The most common adverse reactions reported are poor/reduced appetite, vomiting, lethargy/dullness, and weakness.
- Occasionally, more serious reactions, including severe depression, hemorrhagic diarrhea, collapse, hypoadrenocortical crisis or adrenal necrosis/rupture may occur, and may result in death.

AVOIDING PRACTITIONER PITFALLS WITH CANINE CUSHING'S CASES

Ironically, one of the biggest weaknesses veterinarians have is directly tied to a key reason many of us enter this profession. It's a trait that is also one of our greatest common strengths. Veterinarians derive great pleasure from addressing a problem and fixing it. We may even feel a strong need to solve problems *immediately*. Few things are more gratifying than "fixing" an ill or injured patient. Making an immediate difference for a patient, and for the people who love that animal, is energizing.

While this compulsion often drives veterinarians, it may also hold us back. Patients with Cushing's syndrome and other conditions that require long-term care and ongoing communication with pet owners often do not have an immediate emotional pay-off. In fact, it can be weeks before the earliest positive results are realized. These cases are marathons rather than sprints to glory. The extended and involved nature of these types of conditions can be daunting, and many practitioners feel a subtle, yet persistent desire to refer these patients away.

While some patients with advanced conditions do require referral to veterinary specialists, many cases, especially dogs with canine hyperadrenocorticism, are well within the case management capabilities of general practitioners. They simply require commitment from both the doctor and the client.

Correct the pitfalls that affect your cases

A 2007 review of treatment adherence in human psychiatric patients highlighted four predictors of treatment concordance problems associ-

ated with clinician factors: poor doctor-patient relationship, poor explanation/communication, poor empathy, and inadequate follow-up.¹ By avoiding similar pitfalls in veterinary practice, we can improve patient care and successfully manage more of our canine patients with Cushing's syndrome and other chronic diseases.

Strengthen the doctor-client relationship

Weak doctor-client relationships can lead to client mistrust and low perceptions of value in the services received. A demonstrated long-term commitment to the resolution of a chronic disease such as Cushing's syndrome may be the single strongest medical tool that a veterinarian can employ. Trusted doctor-client relationships can take time to build, and ideally exist before a patient faces a diagnosis of a chronic disease. However, these relationships often must be forged as treatment progresses.

Explain and communicate

Unlike treatments for many acute illnesses, where therapy is performed in the veterinary clinic or for a short time at home, treatments for chronic diseases require client persistence. Pet owners must provide significant ongoing time and financial commitments and discipline in treatment plan adherence. Nothing will make these sacrifices seem unreasonable to clients faster than a veterinarian's poor explanation and communication and a lack of quick results. (See boxed text on page 32, "Effective client communication is key.")

If pet owners don't understand why a treat-

Effective Client Communication is Key

Pet owners may find value in inquiries from their veterinarian such as, "What questions do you have for me?" or statements like, "I'm sure you've heard this before, but I always like to review why we're using the medications and what to expect in the coming weeks. OK?"

Using simple language and metaphors to explain disease states and treatment options will also increase client understanding.

For example, consider offering an ice maker analogy to describe hyperadrenocorticism to clients. You might say to a client, "Think of how an ice maker works. Normally the ice (cortisol) is replenished once it drops below a certain level in the bin. If the mechanism that stops ice production is defective, the ice maker continues to make ice and the bin overflows and fills the freezer, affecting its operation. Treating hyperadrenocorticism involves administering medication to decrease cortisol production and measuring cortisol concentration at regular intervals. This will help keep your dog's cortisol concentrations in check."

ment is being recommended, they are likely to ignore the recommendation or abandon it over time. If they have unrealistic expectations for how quickly or completely clinical signs will be controlled, they may feel disillusioned. We must invest and reinvest our time in educating the client and maintaining reasonable expectations for treatment outcomes.

Empathize

When clients express frustration, it is easy to sympathize, but that's not enough. To help patients and pet owners over the long term, we



Andy Roark, DVM, MS

Dr. Roark is a practicing veterinarian, international speaker, author, and media personality. He is the founder of the Uncharted Veterinary Conference and DrAndyRoark.com. He has been an award-winning columnist for DVM360 and his popular Facebook page, website, and YouTube show reach millions of people every month.

We must invest and reinvest our time in educating the client and maintaining reasonable expectations for treatment outcomes.

must go beyond sympathy and stay actively involved in the situation. We need to put ourselves in the pet owner's shoes — to show true empathy, rather than just sympathy — so that we may share in their emotions and show that we're taking action that improves their experience and the quality of life of their pet.

For example, it's easy to sympathize with a pet owner whose spouse is skeptical or unsupportive of the pet's treatment plan. So to maximize treatment effectiveness, move beyond the role of "sympathetic ear" and help devise solutions. Offer a group consultation so you may review the disease process and the medical rationale behind the treatment to enlist support from previously uninvolved family members. Alternatively, give the pet owner educational materials to share. Regardless of what path you choose, getting involved and sharing the pet owner's experience helps increase the probability of long-term success.

Follow up thoroughly

Veterinarians often tend to consider the appointment "over" as soon as we finish writing up the medical record. This approach is



Avoid Common Relationship and Communication Pitfalls

- Take care to ensure that clients do not feel judged.
- Emphasize your commitment to long-term management of a patient's disease or disease manifestations.
- Provide frequent opportunities for clients to voice their concerns, questions, or frustrations. This may be done through face-to-face interaction at follow-up visits or telephone or electronic communication.
- Always address client concerns promptly and supportively.
- Ensure that the pet owner has reasonable treatment expectations and is satisfied with the level of communication with the practice.
- Offer support and reassurance that, with patience and commitment, the patient's clinical signs can be successfully managed.
- Present a clear explanation of what treatment noncompliance means to a patient's quality of life: continuation, recurrence, or progression of clinical signs, and development of secondary conditions requiring further diagnostics and treatment.

ineffective. Many chronic disease processes, such as Cushing's syndrome, are not cured by your recommended treatment; however, they can be well managed. These patients will need to be treated the rest of their lives. We need to monitor the case to ensure that treatment plans are adjusted as needed and before clients lose faith in the medical management process. Success, in the eyes of the owner and for the patient, requires regular patient evaluation as well as an assessment of client satisfaction. Follow-up phone calls and recheck appointments are essential components of the management plan. As the two Canine Cushing's Case Files articles on pages 26 to 29 described, a practice's entire veterinary team has a role to play in client communication and education.

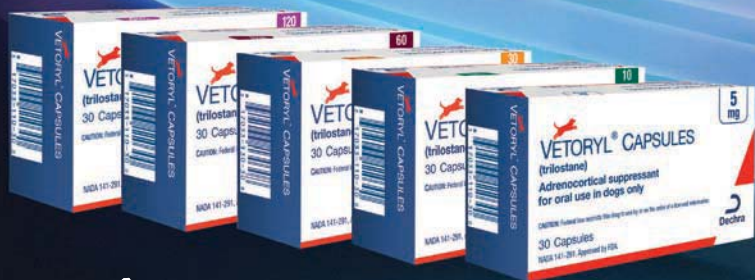When a "fix it" mentality won't fix it

In our busy practices, it is easy to fall into a "fix-it-quick" mentality and slip into these practitioner pitfalls. Dedication to working through these challenges (with the support of resources like the Veterinary Technical Service team at Dechra Veterinary Products) allows us to experience the many rewards that come from building stronger relationships with our clients, managing chronic diseases successfully, and giving suffering patients a new lease on life.

REFERENCE

1. Mitchell AJ, Selmes T. Why don't patients take their medicine? Reasons and solutions in psychiatry. *Adv Psych Treat* 2007; 13:336-346. doi: 10.1192/apt.bp.106.003194. Available at: <http://apt.rcpsych.org/content/13/5/336.full>

Diagnosis, Treatment and Monitoring of Hyperadrenocorticism



VETORYL[®] CAPSULES (trilostane)

CAUTION: Federal (USA) law restricts this drug to use by or on the order of a licensed Veterinarian. As with all drugs, side effects may occur. In field studies and post-approval experience, the most common side effects reported were: anorexia, lethargy/depression, vomiting, diarrhea, elevated liver enzymes, elevated potassium with or without decreased sodium, elevated BUN, decreased Na/K ratio, hypoadrenocorticism, weakness, elevated creatinine, shaking, and renal insufficiency. In some cases, death has been reported as an outcome of these adverse events. VETORYL Capsules are not for use in dogs with primary hepatic or renal disease, or in pregnant dogs. Refer to the prescribing information for complete details or visit www.dechra-us.com.

Confirming the diagnosis of hyperadrenocorticism (HAC)

No test for HAC has 100% diagnostic accuracy. The diagnostic value of all endocrine tests will be significantly enhanced by performing them only when clinical signs consistent with HAC are present in the patient. Three endocrine diagnostic tests are available, all with particular advantages and disadvantages:

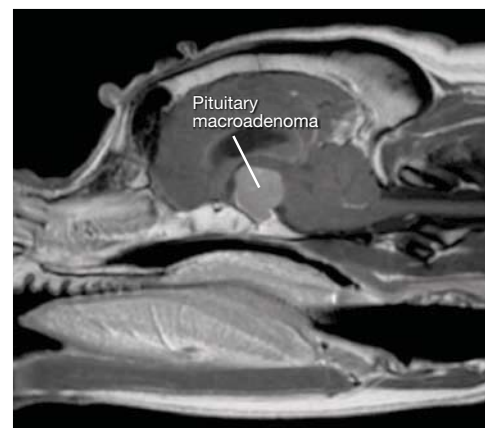Test	Sensitivity & Specificity	Additional info
Urinary Cortisol to Creatinine Ratio (UCCR)	<ul style="list-style-type: none"> • Highest sensitivity of all three tests makes it a great screening test • Highest confidence in a negative test result • Lacks specificity • False positives are relatively common 	<ul style="list-style-type: none"> • To avoid false-positive results, urine samples should be collected at home at least two days after a visit to a veterinary clinic • Collect first urine sample from patient in the morning • Specificity and sensitivity can be increased when urine from 2-3 days is pooled and collectively tested and when the test is performed on dogs showing symptoms consistent with HAC
Low-Dose Dexamethasone Suppression	<ul style="list-style-type: none"> • High sensitivity • High confidence in a negative test result • Moderate specificity • False positives can occur 	<ul style="list-style-type: none"> • Long test (8 hours) • In some cases may differentiate between PDH and ADH • Considered the screening test of choice unless iatrogenic HAC is suspected
ACTH Stimulation	<ul style="list-style-type: none"> • Highest specificity of all three tests • Highest confidence in a positive test result • Lacks sensitivity • False negatives are relatively common 	<ul style="list-style-type: none"> • Relatively short test (1 hour) • Test of choice if there is a history of exogenous steroid therapy

For detailed information on performing and interpreting these tests, please contact Dechra Veterinary Technical Services at (866) 933-2472 or your reference laboratory consult line.

Differentiating between types

It is necessary to differentiate between Pituitary Dependent Hyperadrenocorticism (PDH) and Adrenal Dependent Hyperadrenocorticism (ADH) to provide a more accurate prognosis and enable the full range of possible treatments to be discussed with the dog's owner.

Discriminatory tests available to differentiate between PDH and ADH include the low- and high-dose dexamethasone suppression tests, ultrasonography, and advanced imaging such as MRI and CT and measurement of endogenous ACTH.

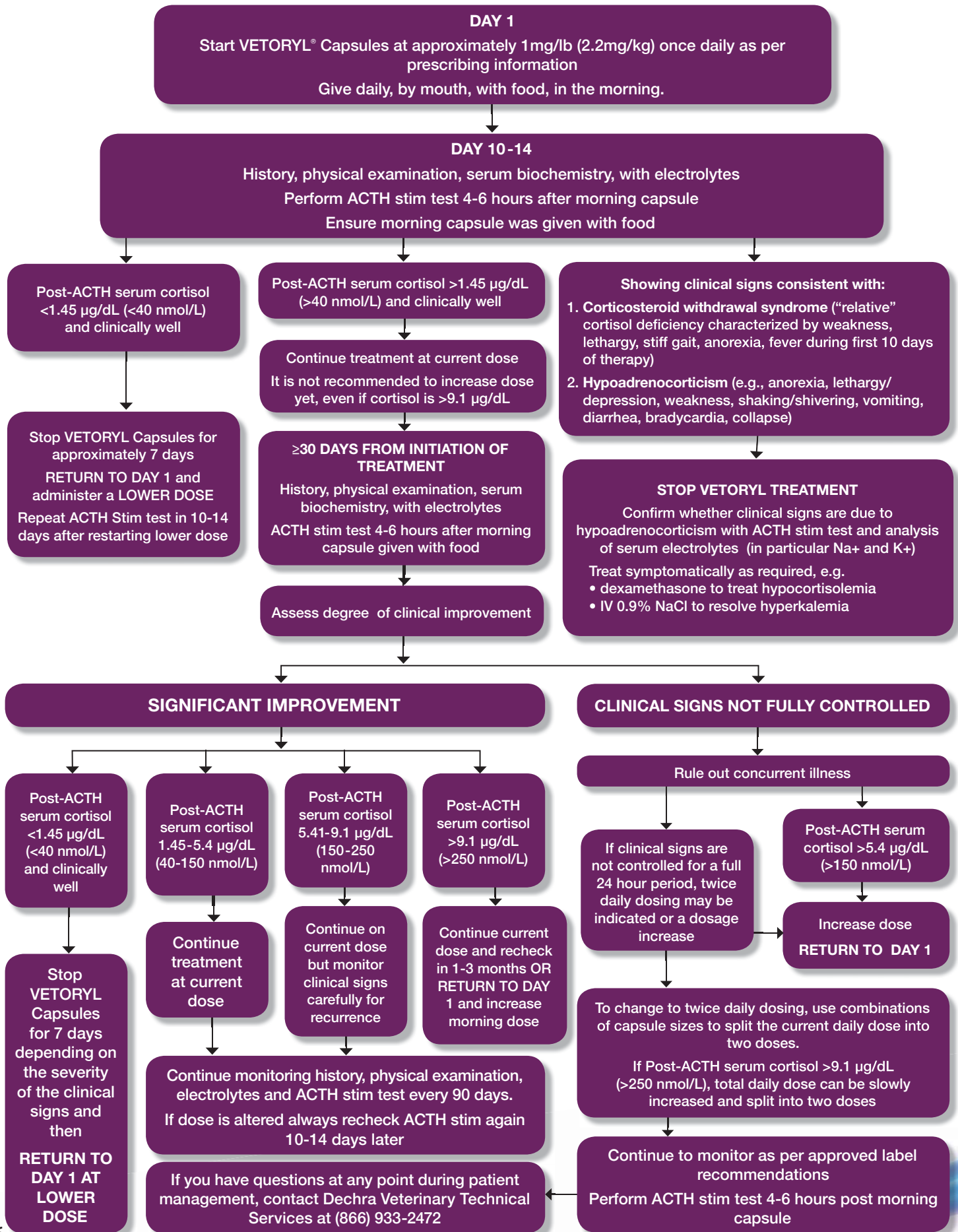


MRI image from a Boxer dog with a pituitary macroadenoma (image courtesy of Ruth Dennis, The Animal Health Trust, UK)

Diagnostic summary

A confident diagnosis requires consistent endocrine confirmatory test results in a dog with clinical signs compatible with hyperadrenocorticism.

Treatment and Monitoring of Hyperadrenocorticism



**Treat their Hyperadrenocorticism.
Help restore their vitality.**



What is canine hyperadrenocorticism?

Canine hyperadrenocorticism (HAC), or Cushing's syndrome, is one of the most commonly diagnosed endocrinopathies in the dog.

Hyperadrenocorticism can be either iatrogenic or naturally occurring (spontaneous).

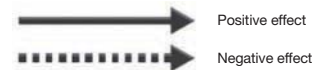
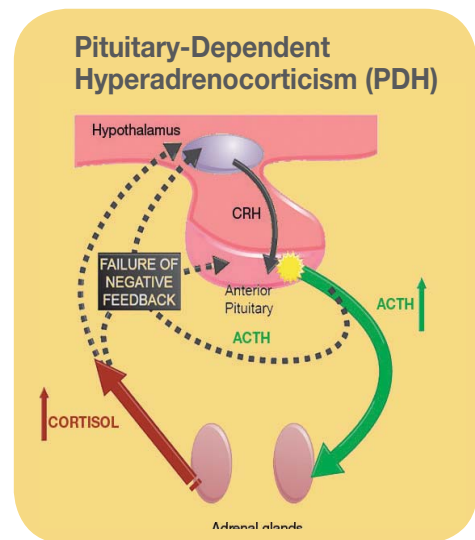
- Iatrogenic cases result from chronic administration of exogenous glucocorticoids.
- Spontaneous cases result from chronic and excessive production of glucocorticoids by the adrenal glands.

Prolonged exposure to high plasma concentrations of glucocorticoids, mainly cortisol, causes a complex of physical and biochemical changes.

Types of hyperadrenocorticism

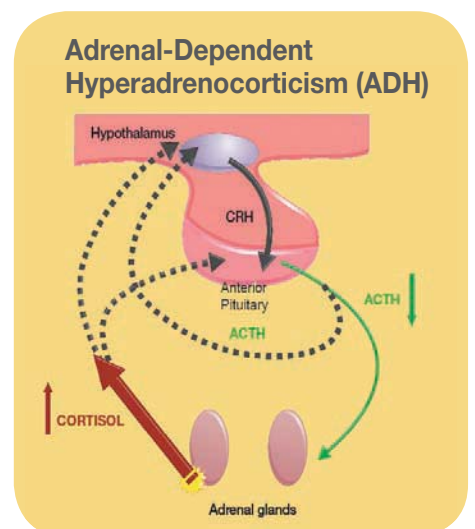
Most spontaneous cases of hyperadrenocorticism (80-85%) are caused by hypersecretion of ACTH (Adrenocorticotrophic Hormone) by a lesion in the pituitary gland. The pituitary lesion is typically a microadenoma of the pars distalis. Macroadenomas are less common.

The overproduction of ACTH in the pituitary leads to bilateral adrenal hyperplasia and increased glucocorticoid (cortisol) secretion.



The remainder of spontaneous cases (15-20%) are caused by an autonomous glucocorticoid (cortisol) producing adrenocortical adenoma or carcinoma.

The hypersecretion of cortisol results in suppression of pituitary ACTH secretion and subsequent atrophy of non-tumorous adrenocortical tissue.



How to deal with hyperadrenocorticism - a three step approach

STEP 1
Diagnose

STEP 2
Treat

STEP 3
Monitor

STEP 1

Diagnose

Clinical Signs

The symptoms of hyperadrenocorticism (HAC) are fairly non-specific and never conclusive for diagnosing the disease.

Table 1. Clinical manifestations of canine HAC. Categorization of frequency is based on identification at the time of initial presentation¹.

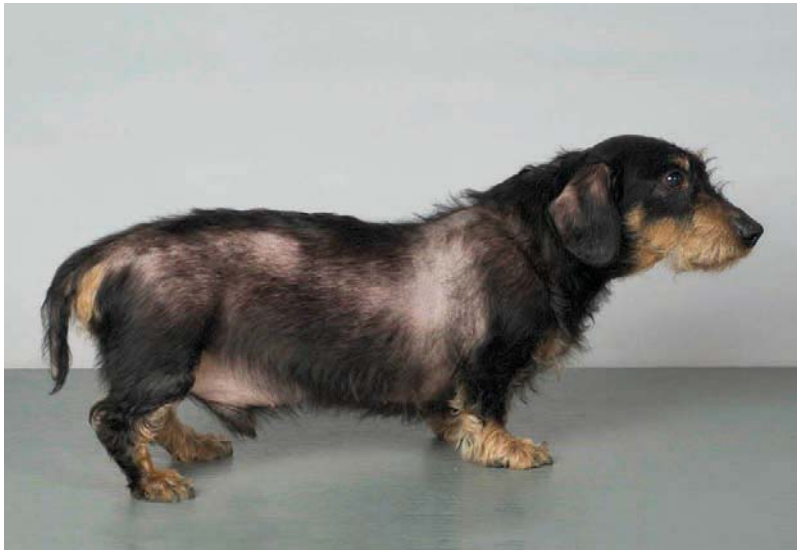Common	Less Common	Uncommon
Polydipsia	Lethargy	Thromboembolism
Polyuria	Hyperpigmentation of skin	Ligament rupture
Polyphagia	Comedones	Facial nerve palsy
Panting	Thin skin	Pseudomyotonia
Abdominal distention	Poor hair regrowth	Testicular atrophy
Endocrine alopecia	Urine leakage	Persistent anestrus
Hepatomegaly	Insulin-resistant diabetes mellitus	
Muscle weakness	Persistent or recurrent UTIs	
Systemic hypertension	Persistent or recurrent skin infections	

Table 2. Common laboratory abnormalities in dogs with HACi.

Complete Blood Count	Serum Biochemistry Panel	Urinalysis
Neutrophilic leukocytosis	Increased alkaline phosphatase	Specific gravity $\leq 1.018-1.020$
Lymphopenia	Increased alanine aminotransferase	Proteinuria
Eosinopenia	Hypercholesterolemia	Indicators of urinary tract infection
Thrombocytosis	Hypertriglyceridemia	
Mild erythrocytosis	Hyperglycemia	

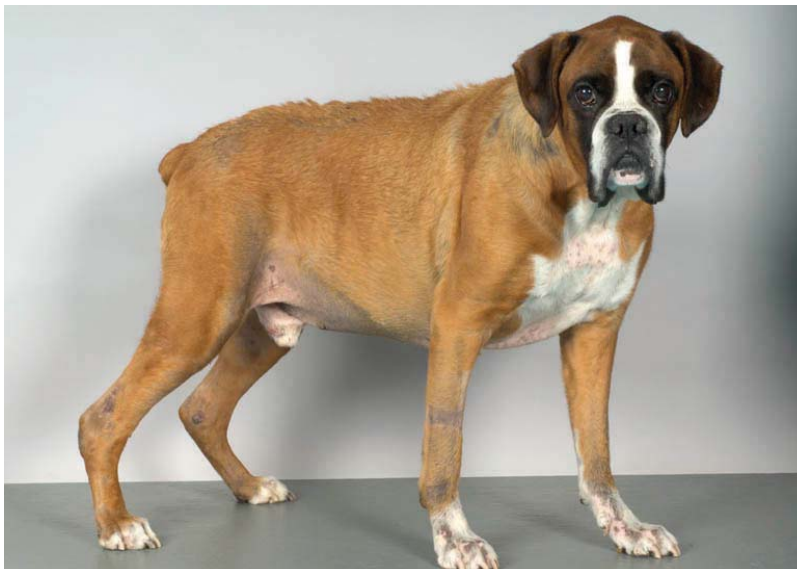Eventually death may result from the complications of untreated HAC that can include diabetes mellitus, systemic hypertension, pancreatitis, urolithiasis, proteinuria, gallbladder mucocele formation and pulmonary thromboembolismⁱⁱ.

However, far before that, HAC will have significantly affected the quality of life of both the dog and its owner.



© Dr. S. Galac

11-year-old Dachshund displaying typical signs of hyperadrenocorticism.



© Dr. S. Galac

10-year-old Boxer displaying typical signs of hyperadrenocorticism.

Diagnosis of Spontaneous Canine Hyperadrenocorticism

A consensus statement¹ published in the Journal of Veterinary Internal Medicine in 2013 offers a consensus opinion on the diagnosis of spontaneous canine hyperadrenocorticism and the reader is advised to read the statement for further detail.

Clinical Presentation: Indications for Diagnostic Testing

- The possibility that a patient has hyperadrenocorticism (HAC) is based on the history and physical examination. Endocrine tests should be performed only when clinical signs consistent with HAC are present.
- The primary indication for pursuing a diagnosis of HAC is the presence of one or more of the common clinical signs and physical examination findings (Table 1).
- The more abnormalities identified, the stronger the indication to pursue endocrine testing.
- If less common clinical presentations are identified first, a thorough review of the history, physical examination findings, and routine laboratory test results (Table 2) often provides additional evidence for the disease.
- Failure to identify abnormalities listed in Tables 1 and 2 is a major negative indicator for the presence of HAC.

Abnormal biochemistry, hematology, urinalysis, and urine protein : creatinine (UPC) ratio results and blood pressure measurement by themselves are not indications to perform endocrine tests.

Diagnostic tests

No test for HAC has 100% diagnostic accuracy. Whichever test is chosen, the diagnostic value of the test will be significantly enhanced by performing endocrine testing only when clinical signs consistent with HAC are present.

Diagnosis of HAC depends on demonstration of either:

- 1) increased cortisol production or
- 2) decreased sensitivity of the hypothalamic-pituitary-adrenal axis (HPAA) to negative glucocorticoid feedback.

Any diagnostic test may be negative in a patient with HAC. If a test is negative but suspicion for HAC remains, another test should be performed. If more than one test is negative, the possibility that the patient does not have HAC must be considered. Alternatively, the patient may have mild HAC and the tests have not yet become positive. It may be worthwhile to retest in 3–6 months if clinical signs progress.

Confirming the diagnosis

Three endocrine diagnostic tests are available, all with particular advantages and disadvantages:

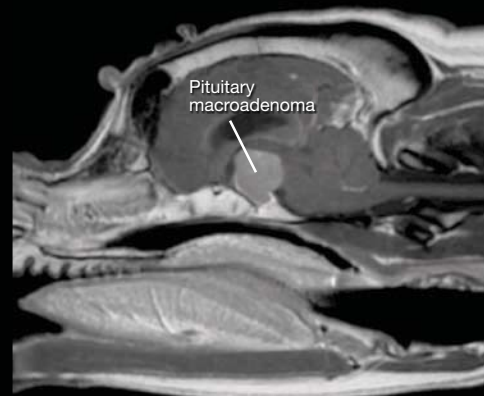Summary based on the 2012 ACVIM Consensus Statement on the diagnosis of spontaneous canine hyperadrenocorticism¹.

Test	Principles	Sensitivity and Specificity	Protocol	Notes
Urine Cortisol: Creatinine Ratio (UCCR)	<p>Provides an integrated reflection of cortisol production, adjusting for fluctuations in blood concentrations</p> <p>A normal UCCR result is almost 100% consistent with the absence of Cushing's syndrome in the patient. Further endocrine testing is generally not recommended.</p>	<p>Sensitivity: 99% (95% CI, 94 - 100%)</p> <p>Specificity: 77% (95% CI, 64 - 87%)</p>	<p>To avoid the influence of stress and false positive results, urine should be collected at home, at least two days after a visit to a veterinary clinic</p> <p>Although a UCCR sample can be collected at any time of day, morning urine is preferred because it usually represents several hours of urine production</p>	<p>A sensitive test to detect cortisol hypersecretion</p> <p>The sensitivity and specificity of this test are greatly reduced when urine collected at a veterinary hospital is tested. (sensitivity ranges from 75 - 100% and specificity 20 - 25%)</p> <p>Specificity and sensitivity can be increased when urine from 2-3 days is pooled and collectively tested, and when the test is performed on dogs showing symptoms consistent with HAC</p>
Low-Dose Dexamethasone Suppression (LDDS)	<p>Evaluates the patient's negative feedback mechanism of the hypothalamic/pituitary/ adrenal axis (HPPA)</p> <p>Dogs with HAC have a diminished ability to decrease cortisol production</p>	<p>Sensitivity: 85-100%</p> <p>Specificity: 44-73%</p>	<p>The LDDST should be performed using 0.01-0.015 mg/kg dexamethasone sodium phosphate or polyethylene glycol IV; calculate dose using the parent compound and not the salt</p> <p>Obtain blood samples before dexamethasone administration and 4 and 8 hours after</p>	<p>The ACVIM panel considers the LDDST as the screening test of choice, unless iatrogenic HAC is suspected</p> <p>The cortisol concentration 8 hours after dexamethasone administration is evaluated to determine if the patient has cortisol overproduction consistent with HAC</p> <p>If the 8 hour cortisol value is elevated, the 4 hour value can help differentiate between PDH and ADH</p>
ACTH Stimulation	<p>Assesses adrenocortical reserve and is the gold standard for diagnosis of iatrogenic HAC</p> <p>Patients with HAC often have an exaggerated response to ACTH administration</p>	<p>Sensitivity: 57 - 95% (all forms of spontaneous HAC) 57 - 63% (ADH) 80 - 83% (PDH)</p> <p>Specificity: 86-93%</p>	<p>Perform the test using 5 µg/kg of synthetic ACTH with blood samples drawn before and 60 minutes after administration</p> <p>The ACVIM panel prefers IV administration</p>	<p>The gold standard for diagnosis of iatrogenic HAC and monitoring of patients with HAC once they have started treatment</p> <p>Because of its lower sensitivity, its diagnostic usefulness as a confirmatory test for spontaneous HAC is inferior to the LDDST</p>

Differentiating between types

It is necessary to differentiate between Pituitary Dependent Hyperadrenocorticism (PDH) and Adrenal Dependent Hyperadrenocorticism (ADH) to provide a more accurate prognosis and enable the full range of possible treatments to be discussed with the dog's owner.

Discriminatory tests available to differentiate between PDH and ADH include the low- and high-dose dexamethasone suppression tests, ultrasonography, and advanced imaging such as MRI and CT, and measurement of endogenous ACTH.



MRI image from a Boxer dog with a pituitary macroadenoma (image courtesy of Ruth Dennis, The Animal Health Trust, UK)

Diagnostic summary

A confident diagnosis requires consistent endocrine confirmatory test results in a dog with clinical signs compatible with hyperadrenocorticism.

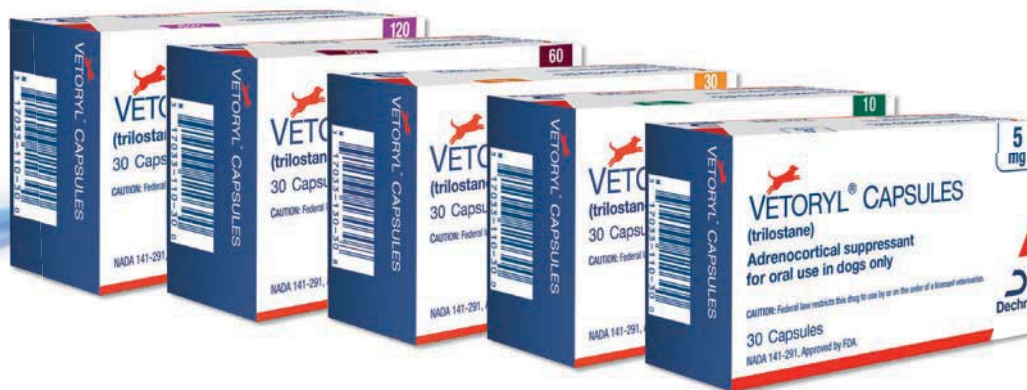

STEP 2 Treat

Treatment of hyperadrenocorticism (HAC) may be achieved by surgery (adrenalectomy or trans-sphenoidal hypophysectomy), pituitary irradiation, or medical treatment. Surgery and radiotherapy are complicated procedures available only at a few specialty centers, therefore medical treatment is often the most practical and approachable treatment choice.

VETORYL[®] CAPSULES (trilostane)

- VETORYL Capsules are the only FDA approved pharmaceutical for the treatment of Pituitary-Dependent Hyperadrenocorticism (PDH) and Adrenal-Dependent Hyperadrenocorticism (ADH) in dogs.
- VETORYL Capsules contain trilostane, which selectively, and reversibly, inhibits the enzyme 3β -hydroxysteroid dehydrogenase, which is involved in the synthesis of several steroids including cortisol and aldosterone.
- At recommended dose rates, VETORYL Capsules tend to have a more selective effect on glucocorticoid productionⁱⁱⁱ, however the potential inhibition of aldosterone must always be borne in mind by the attending clinician.
- VETORYL Capsules reduce circulating cortisol levels, leading to improvement in many of the clinical signs of HAC.
- VETORYL Capsules provide flexible and accurate dosing with five strengths, 5 mg, 10 mg, 30 mg, 60 mg and 120 mg capsules, allowing you to restore the dog's vitality by reducing the clinical signs associated with HAC.
- Available in blister packs of 30 capsules for ease of dispensing.



CAUTION: Federal law restricts this drug to use by or on the order of a licensed veterinarian.
VETORYL is a trademark of Dechra LTD. ©2018, Dechra Ltd.
NADA 141-291, Approved by FDA

Important dosage and administration information

VETORYL Capsules should be administered orally, once daily, with food.

The starting dose is 1-3 mg/lb (2.2-6.7 mg/kg) once a day for the treatment of hyperadrenocorticism in dogs. Start with the lowest possible dose based on body weight and available combinations of capsule sizes.

Once treatment has started, the owner should be advised to monitor the dog's demeanor, appetite and water intake. If the dog shows any signs of being unwell, advise the owner to stop treatment and contact a veterinarian immediately.

The dose should be titrated according to individual response as determined by monitoring of clinical signs, physical examination and laboratory test results (ACTH stimulation test and serum biochemistry, including electrolytes).



Should symptoms not be adequately controlled for an entire 24 hour inter-dose period, consideration should be given to dosing with VETORYL Capsules twice daily.

For further information please refer to the treatment and monitoring flowchart and the full prescribing information.

VETORYL Capsules give you the power to treat PDH and ADH in dogs with the quality assurance and consistency of content and bioavailability that comes with FDA approval. Every VETORYL Capsule will deliver an accurate amount of trilostane to your patient that has proven dissolution, bioavailability and pharmacokinetics. The dose can be altered as necessary, according to both clinical signs and monitoring test results.

Most studies on trilostane have examined dogs that are started on once daily administration.

A few studies^{iv,v,vi,vii} have shown that dogs can be started on trilostane twice daily. However there is no evidence that doing so improves the outcome. Speed of response may improve but equally side effects may increase.

Current evidence would suggest that about 25% of dogs require twice daily trilostane. Conversely 75% of dogs will respond well to once daily dosing.

STEP

3

Monitor

The dose of VETORYL Capsules should be titrated according to individual response as determined by monitoring of clinical signs, physical examination and laboratory test results (ACTH stimulation test and serum biochemistry, including electrolytes).

Once treatment with VETORYL Capsules has been initiated, samples should be taken for biochemistry (including electrolytes) and an ACTH stimulation test 10-14 days later, 30 days later, 90 days later and every 3 months thereafter.

After the administration of VETORYL Capsules with food, cortisol levels are most significantly suppressed for 3 to 8 hours. Therefore, in order to obtain results at the peak time of effect, the ACTH stimulation test should be performed at 4-6 hours post-dosing. This will ensure you are assessing the dog's cortisol levels when they will be at their lowest, thus uncovering any unintended oversuppression of the adrenal glands that would indicate the need to decrease the dose.

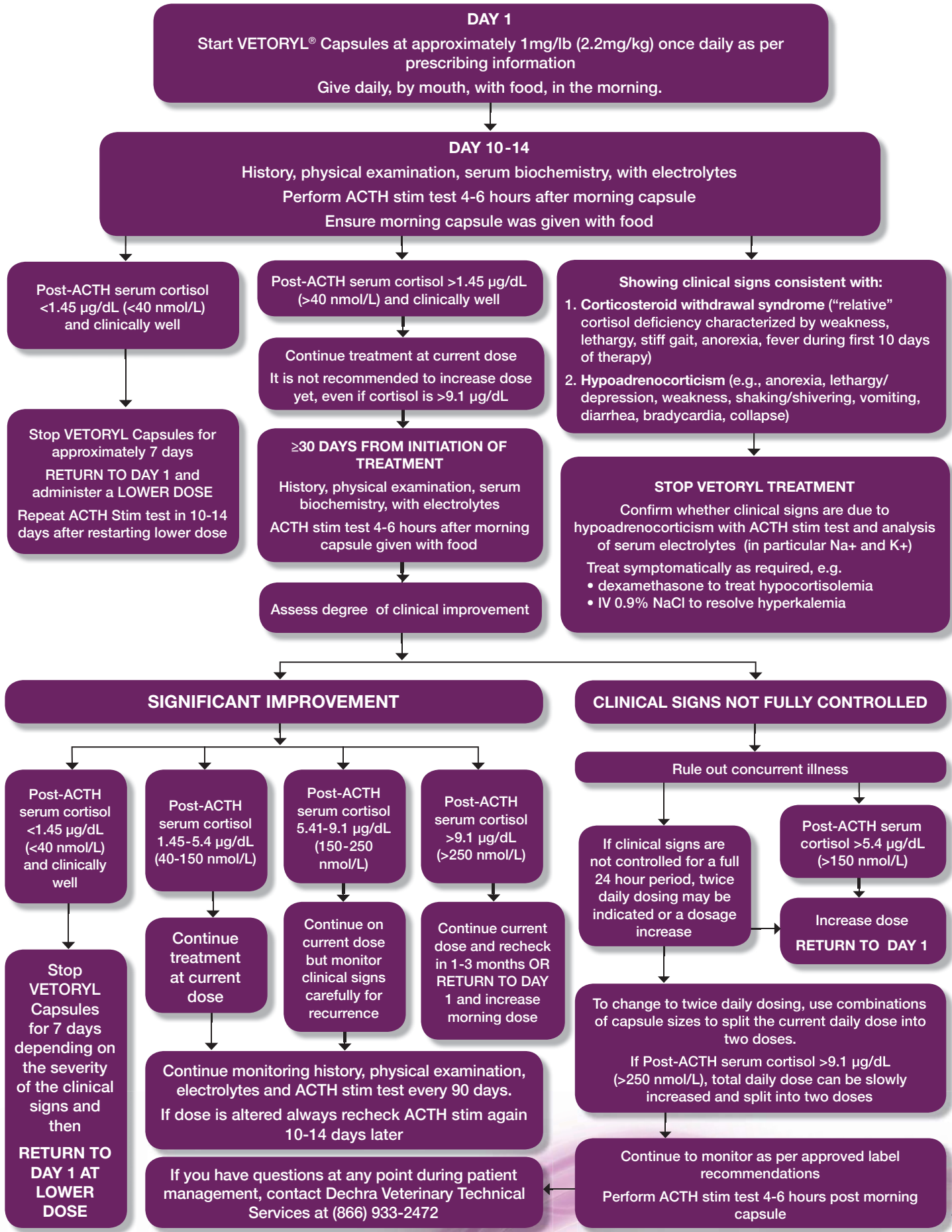
A positive response to the administration of VETORYL Capsules will manifest as an improvement in clinical signs and post-ACTH serum cortisol concentration between 1.45 - 9.1 µg/dL (4-6 hours after dosing with food).

For detailed information on monitoring dogs treated with VETORYL Capsules and guidance on dose changes, please refer to the monitoring and treatment flowchart and the full prescribing information.

Important details to remember:

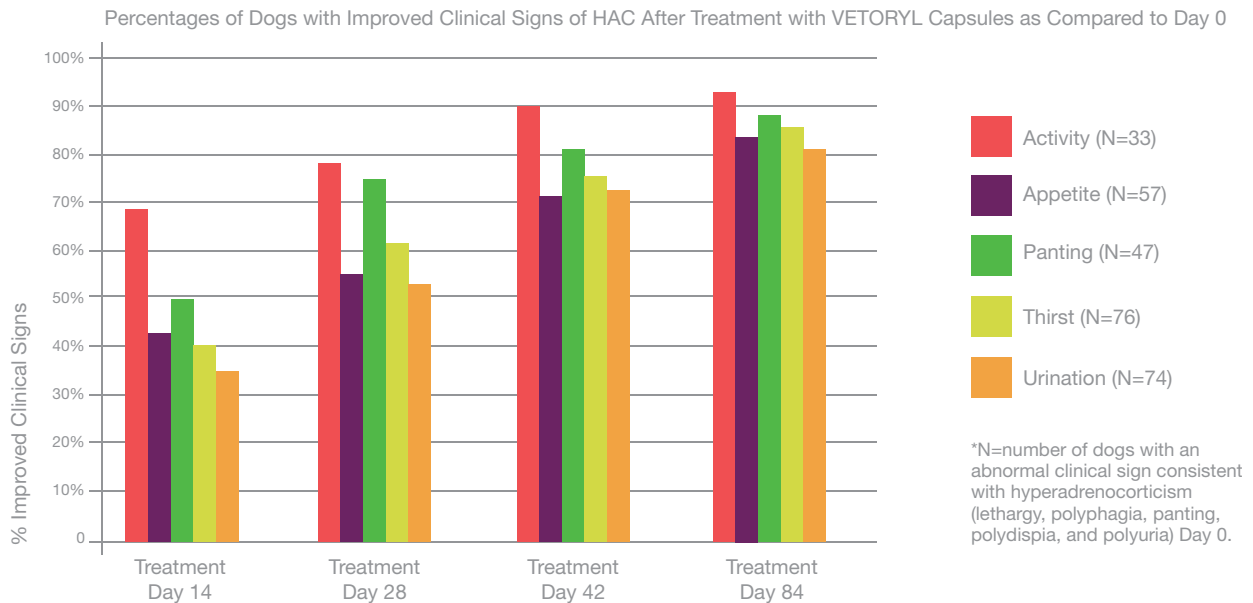
- VETORYL Capsules should be administered with food as this enhances the absorption of trilostane.
- Monitoring is important because patients may need lower doses of VETORYL Capsules after they have been on treatment for a period of time.
- VETORYL Capsules should be administered on the morning of the follow-up ACTH stimulation testing. Due to the peak time of action of trilostane, an ACTH stimulation test should be performed within 4-6 hours after administration of VETORYL Capsules with food.
- Hypoadrenocorticism ('Addisonian crisis') is a known adverse reaction.

Treatment and Monitoring of Hyperadrenocorticism



Efficacy of VETORYL Capsules treatment

Daily administration of VETORYL Capsules can greatly reduce the clinical signs associated with Cushing's syndrome, helping to restore the dog's vitality. Clinical studies demonstrated that treatment with VETORYL Capsules resulted in decreased thirst, decreased frequency of urination, decreased panting, and improvement of appetite and activity.^{viii} Activity levels began to show improvement within 14 days of treatment.



Improvement of clinical signs such as polydipsia, polyuria, polyphagia, panting and lethargy occurs shortly after the start of treatment. Skin, coat and muscle changes take longer to reverse (usually 3-9 months).

As with all drugs, side effects may occur. In field studies and post-approval experience, the most common side effects reported were: anorexia, lethargy/depression, vomiting, diarrhea, elevated liver enzymes, elevated potassium with or without decreased sodium, elevated BUN, decreased Na/K ratio, hypoadrenocorticism, weakness, elevated creatinine, shaking, and renal insufficiency. **In some cases, death has been reported as an outcome of these adverse events.** VETORYL Capsules are not for use in dogs with primary hepatic or renal disease, or in pregnant dogs. Refer to the prescribing information for complete details or visit www.Dechra-US.com.

What you can expect to see

First recheck at 10-14 days

Owners should have noticed that the dog is drinking and urinating less. The animal should be less ravenous and excessive panting should have reduced. Lethargy is another clinical sign of hyperadrenocorticism that rapidly responds to treatment; even at the first 10-14 day check many owners have noticed that their dog has more energy.

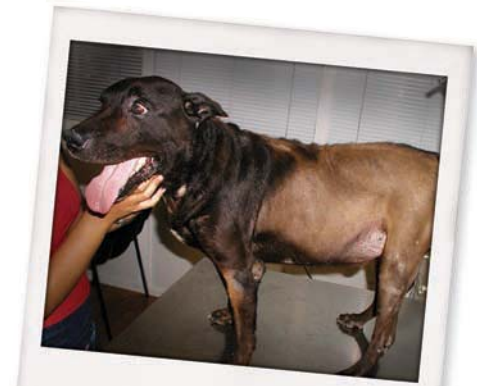Re-examination at 90 days

Abdominal girth reducing, thus pot belly appearance diminishing. Increased muscle tone and strength. Some hair regrowth may be noticeable.

6 months after starting treatment

Most clinical signs of hyperadrenocorticism should have improved or resolved.

At the end of Dechra's 6 month clinical trial of 60 dogs, no more than 15% of dogs exhibited any of the clinical signs associated with hyperadrenocorticism.



Photographs courtesy of Carlos Mellan, DVM, PhD

If cortisol levels have normalized and the dog is still excessively urinating, check a urinalysis for signs of a silent urinary tract infection (UTI). Dogs with HAC often have silent UTIs and if left untreated can cause the polyuria to continue even after the cortisol levels have been controlled.

Optimal support of hyperadrenocorticism

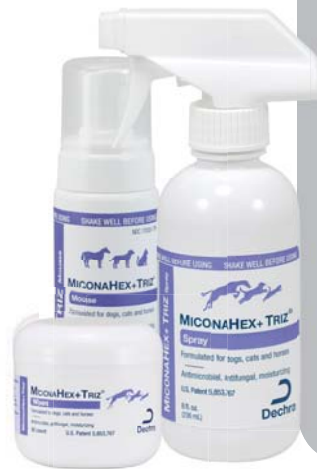Hyperadrenocorticism requires medical or surgical intervention to treat the cortisol overproduction. Some of the common dermatological complications of HAC may benefit from additional supportive measures. Dechra offers a complete line of products to support the restoration of a healthy skin and coat.



MICONAHEX+Triz® Shampoo

A unique combination of 2% miconazole, 2% chlorhexidine, patented USP TrizEDTA, and ceramides.

- Miconazole and chlorhexidine provide antibacterial and antifungal activity to aid in the topical therapy of skin conditions.
- Potentiated with the antibacterial activity of TrizEDTA Plus epidermal barrier repair therapy with the addition of ceramides.



MICONAHEX+Triz® Spray, Wipes, and Mousse

- 2% miconazole, 2% chlorhexidine, TrizEDTA and ceramides
- Available in an easy to use leave-on spray or mousse for use between baths
- Available in easy to use therapeutic wipes for those harder to reach areas like between the toes and in skin folds.



DERMALLAY™ Oatmeal Shampoo

- A soothing, moisturizing oatmeal shampoo
- Useful in restoring coat condition and moisturizing the skin



DERMALLAY™ Oatmeal Spray Conditioner

- A soothing, leave-on oatmeal spray conditioner
- Useful in restoring coat condition and moisturizing the skin



EICOSA3FF® SnipCaps

- Omega-3 fatty acids, DHA and EPA, in the free fatty acid form
- Omega-3 fatty acids can alter the production of eicosanoids & cytokines & support the immune response



DERMALYTE® Shampoo

- Coconut Oil is an emollient and skin moisturizer that increases haircoat body, suppleness and sheen.
- Safflower Oil (linoleic acid) aids in skin moisture retention and soothes dry, itchy skin.
- Ceramides aid in moisturizing, repairing, and restoring dry, damaged skin.

Dechra Veterinary Technical Services

24 hr. support available (866) 933-2472 or contact us at support@dechra.com for non-urgent questions or concerns.

References

- i Behrend *et al* (2013) Diagnosis of Spontaneous Canine Hyperadrenocorticism: 2012 ACVIM Consensus Statement (Small Animal) *JVIM* 1-13
- ii Mooney (2009) Hyperadrenocorticism - to treat or not to treat? *UK Vet* **14(6)**: 1-5
- iii Wenger *et al* (2004) Effects of trilostane on serum concentrations of aldosterone, cortisol and potassium in dogs with pituitary-dependent hyperadrenocorticism. *AJVR* **65(9)**: 245-50
- iv Vaughan *et al* (2008) Evaluation of twice-daily, low dose trilostane treatment administered orally in dogs with naturally occurring hyperadrenocorticism. *JAVMA* **232(9)**: 1321-132
- v Feldman (2011) Evaluation of twice-daily lower-dose trilostane treatment administered orally in dogs with naturally occurring hyperadrenocorticism. *JAVMA* **238**: 1441-1451
- vi Augusto *et al* (2012) A comparison of once and twice daily administration of trilostane to dogs with hyperadrenocorticism. *Tierärztliche Praxis Kleintiere* **40**: 415-424
- vii Cho *et al* (2013) Efficacy of low- and high-dose trilostane treatment in dogs (< 5 kg) with pituitary-dependent hyperadrenocorticism. *JVIM* **27**: 91-98
- viii <http://www.fda.gov/AnimalVeterinary/Products/ApprovedAnimalDrugProducts/FOIADrugSummaries/ucm049823.htm> (accessed December 2014)
- ix Muller *et al* (2012) A review of topical therapy for skin infections with bacteria and yeast. *Veterinary Dermatology* **23**: 330-362

Treat their Cushing's Syndrome.
Help restore their vitality.



www.dechra-us.com

©Dechra Veterinary Products

August 2018

Dechra is a registered trademark of Dechra Pharmaceuticals PLC.

 **VETORYL[®] CAPSULES**
(trilostane)

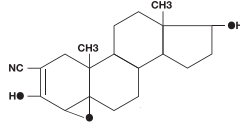


VETORYL[®] CAPSULES (trilostane)

Adrenocortical suppressant for oral use in dogs only.

CAUTION: Federal (USA) law restricts this drug to use by or on the order of a licensed veterinarian.

DESCRIPTION: VETORYL Capsules are available in 5 sizes (5, 10, 30, 60 and 120 mg) for oral administration based on body weight. Trilostane (4 α ,5 α -epoxy-17 β -hydroxy-3-oxoandrostane-2 α -carbonitrile) is an orally active synthetic steroid analogue that selectively inhibits 3 β -hydroxysteroid dehydrogenase in the adrenal cortex, thereby inhibiting the conversion of progesterone to androstenedione. This inhibition blocks production of glucocorticoids and to a lesser extent, mineralocorticoids and sex hormones while steroid precursor levels increase. The structural formula is:



INDICATIONS: VETORYL Capsules are indicated for the treatment of pituitary-dependent hyperadrenocorticism in dogs. VETORYL Capsules are indicated for the treatment of hyperadrenocorticism due to adrenocortical tumor in dogs.

DOSE AND ADMINISTRATION: Always provide the Client Information Sheet with prescription (see **INFORMATION FOR DOG OWNERS**).

1. Starting dose. The starting dose for the treatment of hyperadrenocorticism in dogs is 1-3 mg/lb (2.2-6.7 mg/kg) once a day. Start with the lowest possible dose based on body weight and available combinations of capsule sizes. VETORYL Capsules should be administered with food.

2. Action at 10-14 day evaluation (Table 1). After approximately 10-14 days at this dose, re-examine the dog and conduct a 4-6 hour post-dosing ACTH stimulation test and serum biochemical tests (with particular attention to electrolytes, and renal and hepatic function). If physical examination is acceptable, take action according to Table 1.

Owners should be instructed to stop therapy and contact their veterinarian immediately in the event of adverse reactions such as vomiting, diarrhea, lethargy, poor/reduced appetite, weakness, collapse or any other unusual developments. If these clinical signs are observed, conduct an ACTH stimulation test and serum biochemical tests (with particular attention to electrolytes, and renal and hepatic function).

Table 1: Action at 10-14 day evaluation

Post-ACTH serum cortisol		Action
$\mu\text{g/dL}$	nmol/L	
< 1.45	< 40	Stop treatment. Re-start at a decreased dose
1.45 to 5.4	40 to 150	Continue on same dose
>5.4 to 9.1	> 150 to 250	EITHER: Continue on current dose if clinical signs are well controlled OR: Increase dose if clinical signs of hyperadrenocorticism are still evident*
> 9.1	> 250	Increase initial dose

*Combinations of capsule sizes should be used to slowly increase the once daily dose.

3. Individual dose adjustments and close monitoring are essential. Re-examine and conduct an ACTH stimulation test and serum biochemical tests (with particular attention to electrolytes, and renal and hepatic function) 10-14 days after every dose alteration. Care must be taken during dose increases to monitor the dog's clinical signs.

Once daily administration is recommended. However, if clinical signs are not controlled for the full day, twice daily dosing may be needed. To switch from a once daily dose to a twice daily dose, the total daily dose should be divided into 2 portions given 12 hours apart. It is not necessary for the portions to be equal. If applicable, the larger dose should be administered in the morning and the smaller dose in the evening. For example, a dog receiving 90 mg would receive 60 mg in the morning, and 30 mg in evening.

4. Long term monitoring. Once an optimum dose of VETORYL Capsules has been reached, re-examine the dog at 30 days, 90 days and every 3 months thereafter. At a minimum, this monitoring should include: • A thorough history and physical examination.

• An ACTH stimulation test (conducted 4-6 hours after VETORYL Capsule administration) - a post-ACTH stimulation test resulting in a cortisol of < 1.45 $\mu\text{g/dL}$ (< 40 nmol/L), with or without electrolyte abnormalities, may precede the development of clinical signs of hyperadrenocorticism.

• Serum biochemical tests (with particular attention to electrolytes, and renal and hepatic function). Good control is indicated by favorable clinical signs as well as post-ACTH serum cortisol of 1.45-9.1 $\mu\text{g/dL}$ (40-250 nmol/L).

If the ACTH stimulation test is < 1.45 $\mu\text{g/dL}$ (< 40 nmol/L) and/or if electrolyte imbalances characteristic of hyperadrenocorticism (hyperkalemia and hyponatremia) are found, VETORYL Capsules should be temporarily discontinued until recurrence of clinical signs consistent with hyperadrenocorticism and ACTH stimulation test results return to normal (1.45-9.1 $\mu\text{g/dL}$ or 40-250 nmol/L). VETORYL Capsules may then be re-introduced at a lower dose.

CONTRAINDICATIONS: The use of VETORYL Capsules is contraindicated in dogs that have demonstrated hypersensitivity to trilostane. Do not use VETORYL Capsules in animals with primary hepatic disease or renal insufficiency (See **WARNINGS** and **PRECAUTIONS**). Do not use in pregnant dogs. Studies conducted with trilostane in laboratory animals have shown teratogenic effects and early pregnancy loss.

WARNINGS: Hyperadrenocorticism can develop at any dose of VETORYL Capsules. In some cases, it may take months for adrenal function to return and some dogs never regain adequate adrenal function.

All dogs should undergo a thorough history and physical examination before initiation of therapy with VETORYL Capsules. Other conditions, such as primary hepatic and/or renal disease should be considered when the patient is exhibiting signs of illness in addition to signs of hyperadrenocorticism (e.g. vomiting, diarrhea, poor/reduced appetite, weight loss, and lethargy). Appropriate laboratory tests to establish hematological and serum biochemical baseline data prior to, and periodically during, administration of VETORYL Capsules should be considered.

Owners should be advised to discontinue therapy immediately and contact their veterinarian if signs of potential drug toxicity are observed (see **INFORMATION FOR DOG OWNERS, DOSE AND ADMINISTRATION, PRECAUTIONS, ADVERSE REACTIONS, ANIMAL SAFETY** and **POST-APPROVAL EXPERIENCE**).

In case of overdose, symptomatic treatment of hyperadrenocorticism with corticosteroids, mineralocorticoids and intravenous fluids may be required.

Angiotensin converting enzyme (ACE) inhibitors should be used with caution with VETORYL Capsules, as both drugs have aldosterone-lowering effects which may be additive, impairing the patient's ability to maintain normal electrolytes, blood volume and renal perfusion. Potassium sparing diuretics (e.g. spironolactone) should not be used with VETORYL Capsules as both drugs have the potential to inhibit aldosterone, increasing the likelihood of hyperkalemia.

HUMAN WARNINGS: Keep out of reach of children. Not for human use.

Wash hands after use. Do not empty capsule contents and do not attempt to divide the capsules. Do not handle the capsules if pregnant or if trying to conceive. Trilostane is associated with teratogenic effects and early pregnancy loss in laboratory animals. In the event of accidental ingestion/overdose, seek medical advice immediately and take the labeled container with you.

PRECAUTIONS: Mitotane (o,p'-DDD) treatment will reduce adrenal function. Experience in foreign markets suggests that when mitotane therapy is stopped, an interval of at least one month should elapse before the introduction of VETORYL Capsules. It is important to wait for both the recurrence of clinical signs consistent with hyperadrenocorticism, and a post-ACTH cortisol level of > 9.1 $\mu\text{g/dL}$ (> 250 nmol/L) before treatment with VETORYL Capsules is initiated. Close monitoring of adrenal function is advised, as dogs previously treated with mitotane may be more responsive to the effects of VETORYL Capsules.

The use of VETORYL Capsules will not affect the adrenal tumor itself. Adrenalectomy should be considered as an option for cases that are good surgical candidates. The safe use of this drug has not been evaluated in lactating dogs and males intended for breeding.

ADVERSE REACTIONS: The most common adverse reactions reported are poor/reduced appetite, vomiting, lethargy/dullness, diarrhea, and weakness. Occasionally, more serious reactions, including severe depression, hemorrhagic diarrhea, collapse, hyperadrenocortical crisis or adrenal necrosis/rupture may occur, and may result in death.

In a US field study with 107 dogs, adrenal necrosis/rupture (two dogs) and hyperadrenocorticism (two dogs) were the most severe adverse reactions in the study. One dog died suddenly of adrenal necrosis, approximately one week after starting trilostane therapy. One dog developed an adrenal rupture, believed to be secondary to adrenal necrosis, approximately six weeks after starting trilostane therapy. This dog responded to trilostane discontinuation and supportive care.

Two dogs developed hyperadrenocorticism during the study. These two dogs had clinical signs consistent with hyperadrenocorticism (lethargy, anorexia, collapse) and post-ACTH cortisol levels $\leq 0.3 \mu\text{g/dL}$. Both dogs responded to trilostane discontinuation and supportive care, and one dog required continued treatment for hyperadrenocorticism (glucocorticoids and mineralocorticoids) after the acute presentation.

Additional adverse reactions were observed in 93 dogs. The most common of these included diarrhea (31 dogs), lethargy (30 dogs), inappetence/anorexia (27 dogs), vomiting (28 dogs), musculoskeletal signs (lameness, worsening of degenerative joint disease) (25 dogs), urinary tract infection (UTI/hematuria) (17 dogs), shaking/shivering (10 dogs), otitis externa (8 dogs), respiratory signs (coughing, congestion) (7 dogs), and skin/coat abnormality (seborrhea, pruritus) (8 dogs).

Five dogs died or were euthanized during the study (one dog secondary to adrenal necrosis, discussed above, two dogs due to progression of pre-existing congestive heart failure, one dog due to progressive central nervous system signs, and one dog due to cognitive decline leading to inappropriate elimination). In addition to the two dogs with adrenal necrosis/rupture and the two dogs with hyperadrenocorticism, an additional four dogs were removed from the study as a result of possible trilostane-related adverse reactions, including collapse, lethargy, inappetence, and trembling.

Complete blood counts conducted pre- and post-treatment revealed a statistically significant ($p < 0.005$) reduction in red cell variables (HCT, HGB, and RBC), but the mean values remained within the normal range. Additionally, approximately 10% of the dogs had elevated BUN values ($\geq 40 \text{ mg/dL}$) in the absence of concurrent creatinine elevations. In general, these dogs were clinically normal at the time of the elevated BUN.

In a long term follow-up study of dogs in the US effectiveness study, the adverse reactions were similar to the short term study. Vomiting, diarrhea and general gastrointestinal signs were most commonly observed. Lethargy, inappetence/anorexia, heart murmur or cardiopulmonary signs, inappropriate urination/incontinence, urinary tract infections or genitourinary disease, and neurological signs were reported. Included in the US follow-up study were 14 deaths, three of which were possibly related to trilostane. Eleven dogs died or were euthanized during the study for a variety of conditions considered to be unrelated to or to have an unknown relationship with administration of trilostane.

In two UK field studies with 75 dogs, the most common adverse reactions seen were vomiting, lethargy, diarrhea/loose stools, and anorexia. Other adverse reactions included: nocturia, conical urol, cough, persistent estrus, vaginal discharge and vulvar swelling in a spayed female, hyperadrenocorticism, electrolyte imbalance (elevated potassium with or without decreased sodium), collapse and seizure, shaking, muscle tremors, constipation, scratching, weight gain, and weight loss. One dog died of congestive heart failure and another died of pulmonary thromboembolism. Three dogs were euthanized during the study. Two dogs had renal failure and another had worsening arthritis and deterioration of appetite.

In a long term follow-up of dogs included in the UK field studies, the following adverse reactions were seen: hyperadrenocortical episode (including syncope, tremor, weakness, and vomiting), hyperadrenocortical crisis or renal failure (including azotemia, vomiting, dehydration, and collapse), chronic intermittent vaginal discharge, hemorrhagic diarrhea, occasional vomiting, and distal limb edema. Signs of hyperadrenocorticism were usually reversible after withdrawal of the drug, but may be permanent. One dog discontinued VETORYL Capsules and continued to have hyperadrenocorticism when evaluated a year later. Included in the follow-up were reports of deaths, at least 5 of which were possibly related to use of VETORYL Capsules. These included dogs that died or were euthanized because of renal failure, hyperadrenocortical crisis, hemorrhagic diarrhea, and hemorrhagic gastroenteritis.

Foreign Market Experience: The following events were reported voluntarily during post-approval use of VETORYL Capsules in foreign markets. The most serious adverse events were death, adrenal necrosis, hyperadrenocorticism (electrolyte alterations, weakness, collapse, anorexia, lethargy, vomiting, diarrhea, and azotemia), and corticosteroid withdrawal syndrome (weakness, lethargy, anorexia, and weight loss). Additional adverse events included: renal failure, diabetes mellitus, pancreatitis, autoimmune hemolytic anemia, vomiting, diarrhea, anorexia, skin reactions (rash, erythematous skin eruptions), hind limb paresis, seizures, neurological signs from growth of macroadenomas, oral ulceration, and muscle tremors.

POST-APPROVAL EXPERIENCE: As of June 2013, the following adverse events are based on post-approval adverse drug experience reporting. Not all adverse reactions are reported to FDA CVM. It is not always possible to reliably estimate the adverse event frequency or establish a causal relationship to product exposure using this data. The following adverse events are listed in decreasing order of reporting frequency: anorexia, lethargy/depression, vomiting, diarrhea, elevated liver enzymes, elevated potassium with or without decreased sodium, elevated BUN, decreased Na/K ratio, hyperadrenocorticism, weakness, elevated creatinine, shaking, renal insufficiency. In some cases, death has been reported as an outcome of the adverse events listed above.

For a cumulative listing of adverse reactions for trilostane reported to the CVM see: <http://www.fda.gov/ADREports>

This listing includes Adverse Events reported to CVM for products, such as VETORYL Capsules, that contain the active ingredient trilostane. Listings by active ingredient may represent more than one brand name.

To report suspected adverse events and/or obtain a copy of the MSDS or for technical assistance, call Dechra Veterinary Products at (866) 933-2472.

For additional information about adverse drug experience reporting for animal drugs, contact FDA at 1-888-FDA-VETS or online at: <http://www.fda.gov/AnimalVeterinary/SafetyHealth>

INFORMATION FOR DOG OWNERS: Owners should be aware that the most common adverse reactions may include: an unexpected decrease in appetite, vomiting, diarrhea, or lethargy and should receive the Client Information Sheet with the prescription. Owners should be informed that control of hyperadrenocorticism should result in resolution of polyphagia, polyuria and polydipsia. **Serious adverse reactions associated with this drug can occur without warning and in some cases result in death (see ADVERSE REACTIONS and POST-APPROVAL EXPERIENCE).**

Owners should be advised to discontinue VETORYL Capsules and contact their veterinarian immediately if signs of intolerance such as vomiting, diarrhea, lethargy, poor/reduced appetite, weakness, or collapse are observed. Owners should be advised of the importance of periodic follow-up for all dogs during administration of VETORYL Capsules.

CLINICAL PHARMACOLOGY: Trilostane absorption is enhanced by administration with food. In healthy dogs, maximal plasma levels of trilostane occur within 1.5 hours, returning to baseline levels within twelve hours, although large inter-dog variation occurs. There is no accumulation of trilostane or its metabolites over time.

EFFECTIVENESS: Eighty-three dogs with hyperadrenocorticism were enrolled in a multi-center US field study. Additionally, 30 dogs with hyperadrenocorticism were enrolled in two UK field studies. Results from these studies demonstrated that treatment with VETORYL Capsules resulted in an improvement in clinical signs (decreased thirst, decreased frequency of urination, decreased panting, and improvement of appetite and activity). Improvement in post-ACTH cortisol levels occurred in most cases within 14 days of starting VETORYL Capsules therapy.

In these three studies, there were a total of 10 dogs diagnosed with hyperadrenocorticism due to an adrenal tumor or due to concurrent pituitary and adrenal tumors. Evaluation of these cases failed to demonstrate a difference in clinical, endocrine, or biochemical response when compared to cases of pituitary-dependent hyperadrenocorticism.

ANIMAL SAFETY: In a laboratory study, VETORYL Capsules were administered to 8 healthy 6 month old Beagles per group at 0X (empty capsules), 1X, 3X, and 5X the maximum starting dose of 6.7 mg/kg twice daily for 90 days. Three animals in the 3X group (receiving 20.1 mg/kg twice daily) and five animals in the 5X group (receiving 33.5 mg/kg twice daily) died between Days 23 and 46. They showed one or more of the following clinical signs: decreased appetite, decreased activity, weight loss, dehydration, soft stool, slight muscle tremors, diarrhea, lateral recumbency, and staggering gait. Bloodwork showed hyponatremia, hyperkalemia, and azotemia, consistent with hyperadrenocortical crisis. Post-mortem findings included epithelial necrosis or cystic dilation of duodenal mucosal crypts, gastric mucosal or thymic hemorrhage, atrial thrombosis, pyelitis and cystitis, and inflammation of the lungs.

ACTH stimulated cortisol release was reduced in all dogs treated with VETORYL Capsules. The dogs in the 3X and 5X groups had decreased activity. The 5X dogs had less weight gain than the other groups. The 3X and 5X dogs had lower sodium, albumin, total protein, and cholesterol compared to the control dogs. The 5X dogs had lower mean corpuscular volume than the controls. There was a dose dependent increase in amylase. Post-mortem findings included dose dependent adrenal cortical hypertrophy.

STORAGE INFORMATION: Store at controlled room temperature 25°C (77°F) with excursions between 15°-30°C (59°-86°F) permitted.

HOW SUPPLIED: VETORYL Capsules are available in 5, 10, 30, 60 and 120 mg strengths, packaged in aluminum foil blister cards of 10 capsules, with 3 cards per carton.

VETORYL Capsules 5 mg	NDC 17033-105-30
VETORYL Capsules 10 mg	NDC 17033-110-30
VETORYL Capsules 30 mg	NDC 17033-130-30
VETORYL Capsules 60 mg	NDC 17033-160-30
VETORYL Capsules 120 mg	NDC 17033-112-30

TAKE TIME TO OBSERVE LABEL DIRECTIONS

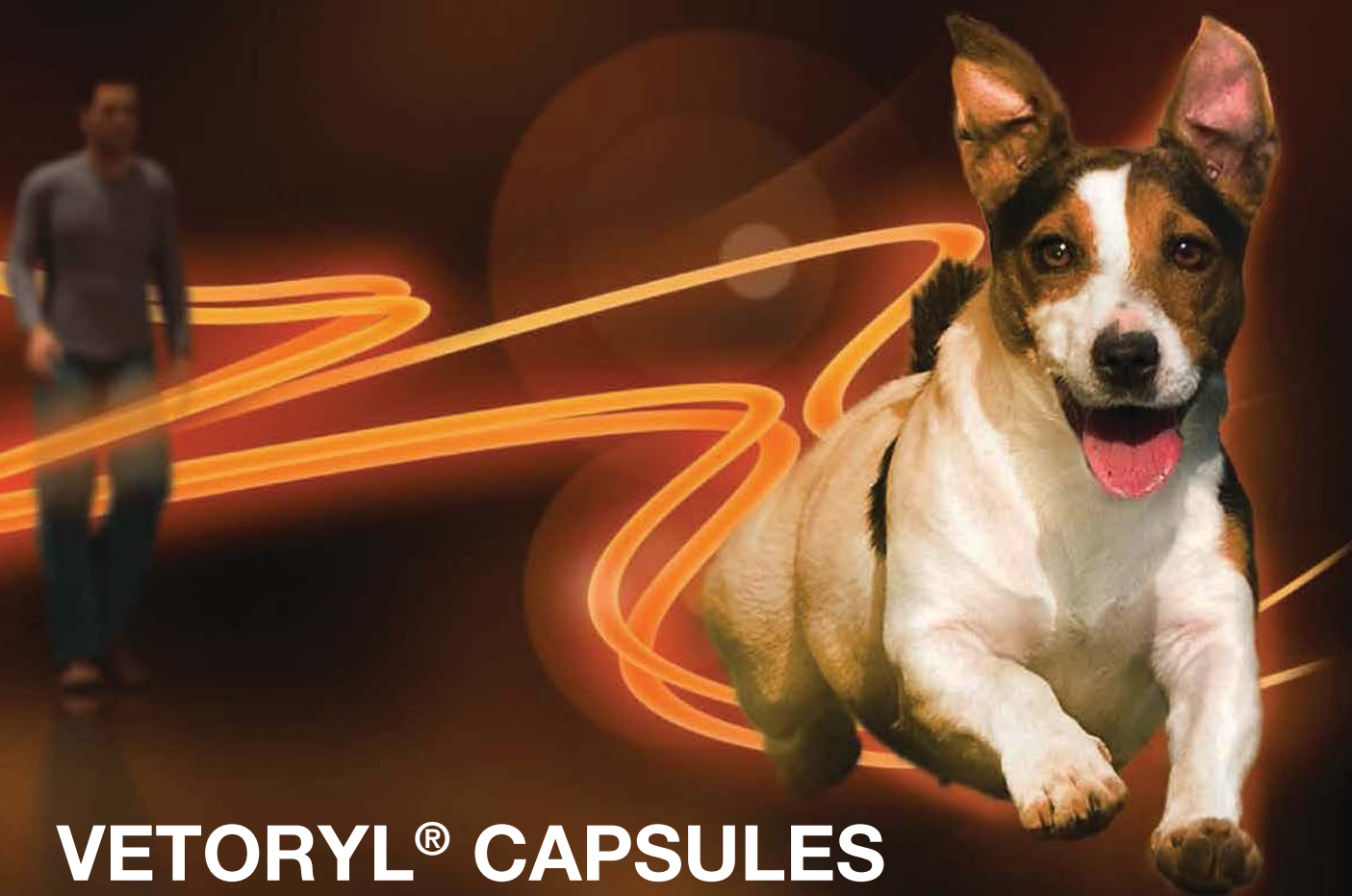NADA 141-291, Approved by FDA.

Distributed by:
Dechra Veterinary Products
7015 College Boulevard, Suite 525
Overland Park, KS 66211

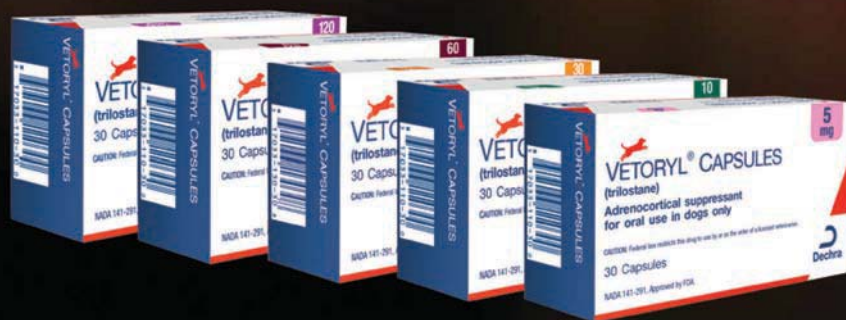VETORYL is a trademark of Dechra Ltd © 2015, Dechra Ltd



Dechra
Veterinary Products



VETORYL® CAPSULES
(trilostane)
are available in a
strength for any size dog.



VETORYL is a trademark of Dechra LTD. ©2018, Dechra Ltd.
NADA 141-291, Approved by FDA
CAUTION: Federal law restricts this drug to use by or on the order of licensed veterinarian.
¹ <https://animaldrugsatfda.fda.gov/adafda/app/search/public/document/downloadFoi/855>

Dechra is a registered trademark of
of Dechra Pharmaceuticals PLC.